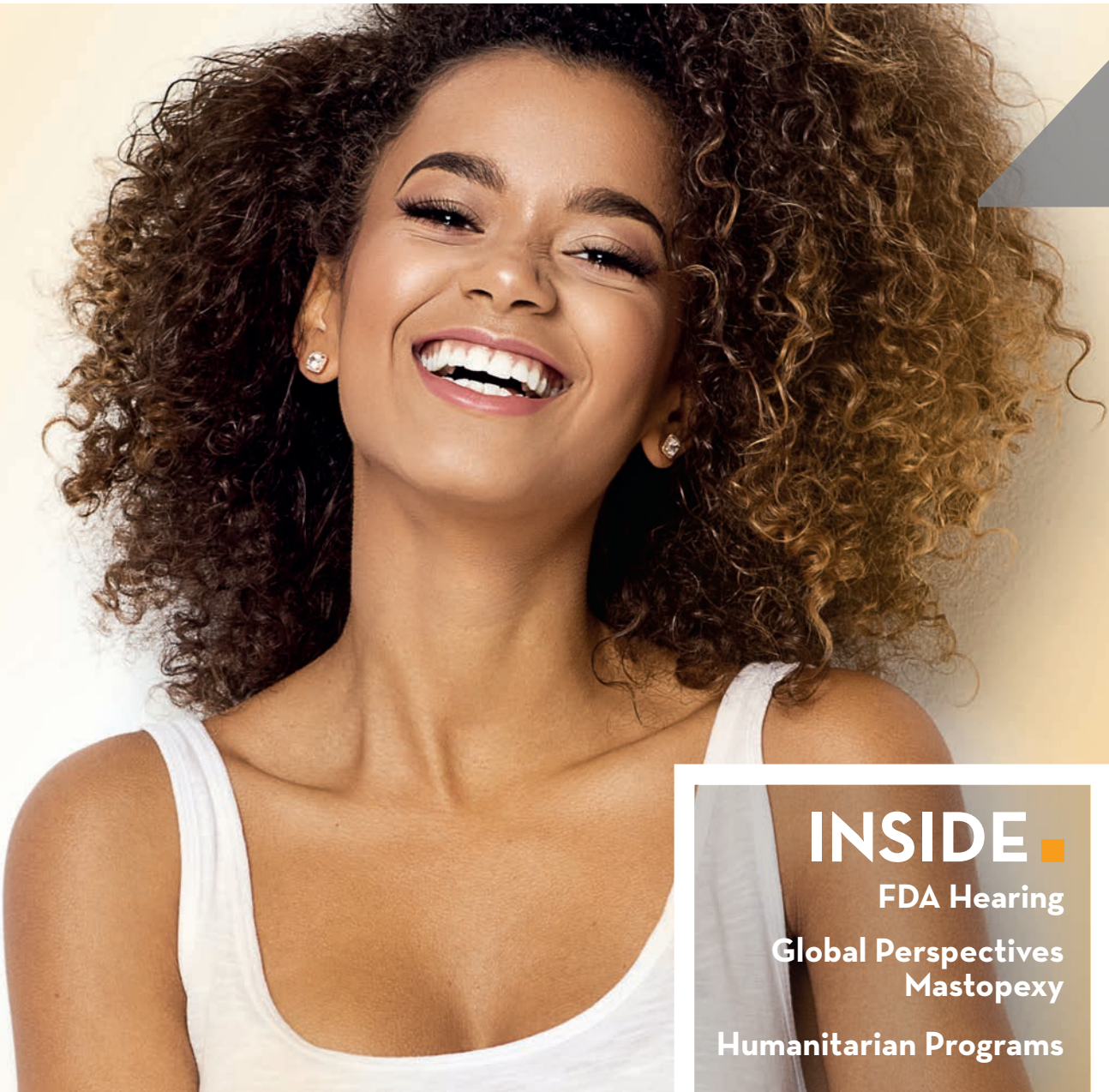

ISAPS NEWS

OFFICIAL NEWS OF THE INTERNATIONAL
SOCIETY OF AESTHETIC PLASTIC SURGERY

2

Volume 13 | Number 2



INSIDE ■
FDA Hearing
Global Perspectives
Mastopexy
Humanitarian Programs

BOARD OF DIRECTORS

PRESIDENT

Dirk Richter, MD, PhD
Wesseling, GERMANY
president@isaps.org

PRESIDENT-ELECT

Nazim Cerkes, MD, PhD
Istanbul, TURKEY
ncerkes@hotmail.com

FIRST VICE PRESIDENT

Lina Triana, MD
Cali, COLOMBIA
linatriana@drlinatriana.com

SECOND VICE PRESIDENT

Gianluca Campiglio, MD, PhD
Milan, ITALY
info@gianlucacampiglio.it

THIRD VICE PRESIDENT

Arturo Ramirez-Montanana, MD
Monterrey, MEXICO
docarturo@gmail.com

SECRETARY

Ivar van Heijningen, MD
Knokke-Heist, BELGIUM
i.vanheijningen@duinbergen-clinic.be

TREASURER

Kai-Uwe Schlaudraff, MD, FEBOPRAS
Geneva, SWITZERLAND
schlaudraff@concept-clinic.ch

HISTORIAN

Peter Scott, MD
Johannesburg, SOUTH AFRICA
peters@cinet.co.za

PARLIAMENTARIAN

Tim Papadopoulos, MD
Sydney, AUSTRALIA
drtim@drtim.com.au

EDUCATION COUNCIL CHAIR

Vakis Kontoes, MD, PhD
Athens, GREECE
vakiskont@gmail.com

EDUCATION COUNCIL VICE CHAIR

Ozan Sozer, MD
El Paso, Texas, US
doctor@elpasoplasticsurgery.com

NATIONAL SECRETARIES CHAIR

Michel Rouif, MD
Tours, FRANCE
michel.rouif@wanadoo.fr

PAST PRESIDENT

Renato Saltz MD, FACS
Salt Lake City, Utah, US
rsaltz@saltzplasticsurgery.com

TRUSTEES

Fabian Cortinas MD
Buenos Aires, ARGENTINA
fabiancortinas@gmail.com

Nina Naidu, MD, FACS
New York, New York, US
drnaidu@naiduplasticsurgery.com

EXECUTIVE DIRECTOR

Catherine Foss
Hanover, New Hampshire, US
isaps@isaps.org

iz2

VOLUME 13

CONTENTS

Message from the Editor	3
Message from the President	4
Global Alliance	7
Guess Who	9
Education Council Update	10
Course Report	12
Visiting Professor Program	13
Feature: FDA Hearing	18
Feature: Apple Worm	20
Humanitarian	22
Committee Report	23
National Secretaries	24
ISAPS BOD	27
Journal Update	28
Marketing	29
Case Study	32
Global Perspectives	34
Surgical Marking	58
History	63
In Memoriam	66
New Members	68
Meetings Calendar	70

MESSAGE FROM

the editor

Dear Colleagues,

Welcome to the second *ISAPS News* issue of 2019. You will notice that we have expanded upon our goal of targeted issues which highlight specific surgical topics. This issue is dedicated to the study of mastopexy. Within the Global Perspectives and Marking sections, you will find an array of articles by surgeons from around the world who have shared their knowledge, tips, and techniques regarding breast lift surgery. Although this procedure is a standard one taught in residency, it has many variations and nuances. I hope that you will find this mini-symposium as fascinating and instructive as I did.

I would also urge you to read Dr. Mark Jewell's important article reporting on the recent Food and Drug Administration (FDA) hearings in the United States on the topics of Anaplastic Large Cell Lymphoma (ALCL) and Breast Implant Illness (BII). The FDA stated in May that the approved macrotexture implant known as BioCell (Allergan) along with other approved textured surface implants/tissue expanders would continue to be approved for sale and use in the United States. We expect that the FDA will however issue new guidance instructions for these devices, including a "Black Box Warning" (an alert that a drug or device has specific greater levels of risk of adverse events associated with its use), informed consent instructions, and a checklist regarding the use of these implants. Although the majority of our members do not practice in the United States, the FDA decision is still critical as they often set a precedent for other countries' health boards.



Our next issue will be dedicated to peri-orbital rejuvenation, including both surgical and non-surgical modalities. We welcome your submissions of original articles and markings related to this topic, in addition to our regular columns which include the history of plastic surgery, patient safety, marketing, humanitarian missions, members' book publication announcements, and memorials to our deceased colleagues.

Please note the strict requirements for accepted articles:

- 1) At least one of the authors must be an active member of ISAPS;
- 2) The articles must be written in standard English; we are unable to perform language editing, and unclear articles will be returned for editing or rejected;
- 3) Images must be sent in jpg form and be of high quality. Small images taken with phones will not be printed (images must be at least 300 dpi);
- 4) Papers must be submitted in their final form prior to the deadline; re-submissions with additional edits after the deadline cannot be accepted.

Thank you for supporting ISAPS. If you are not yet a member, I urge you to join us.

A handwritten signature in black ink that reads "Nina S. Naidu MD FACS".

Nina Naidu, MD, FACS - United States
Editor-in-Chief



WE HAVE CONTRACTED A PATIENT INFORMATION SYSTEM THAT INFORMS AND EDUCATES YOUR PATIENTS FULLY AUTOMATICALLY WITH INFORMATION BEFORE AND AFTER THE OPERATION.



MESSAGE FROM the President

Dear Friends and Colleagues,

ISAPS News is on its way. New design, new editor-in-chief and now also new structure and content. Thank you very much for the many appreciative words about the last issue.

This time we will give you many new insights into current topics like BIA-ALCL, mastopexy, and our expanded Residents and Fellows program.

BIA-ALCL

I am pleased to inform you that most authorities see no reason to withdraw textured breast implants from the market. A landmark decision was recently made by the American Food and Drug Administration (FDA). After a two-day public hearing, those responsible saw no convincing justification for withholding textured breast implants from our patients. The data were too limited and the morbidity probability very low. There are 641 known cases of BIA-ALCL and 21 deaths since 1997, and the chances of cure are exceptionally good. You can see an expanded report on page 18.

As a responsible professional society, we focus on informing our members, but also patients and general practitioners. In the next issue, I will tell you more about the large-scale educational project that we are currently developing.

New Membership Structure Successful

During our board meeting on May 17, just prior to the ASAPS meeting in New Orleans, we discussed and initiated many interesting projects. I was particularly pleased to learn how successfully our new membership fee structure was accepted. Membership dues are now à la carte to meet the many needs and opportunities we have as an international society.

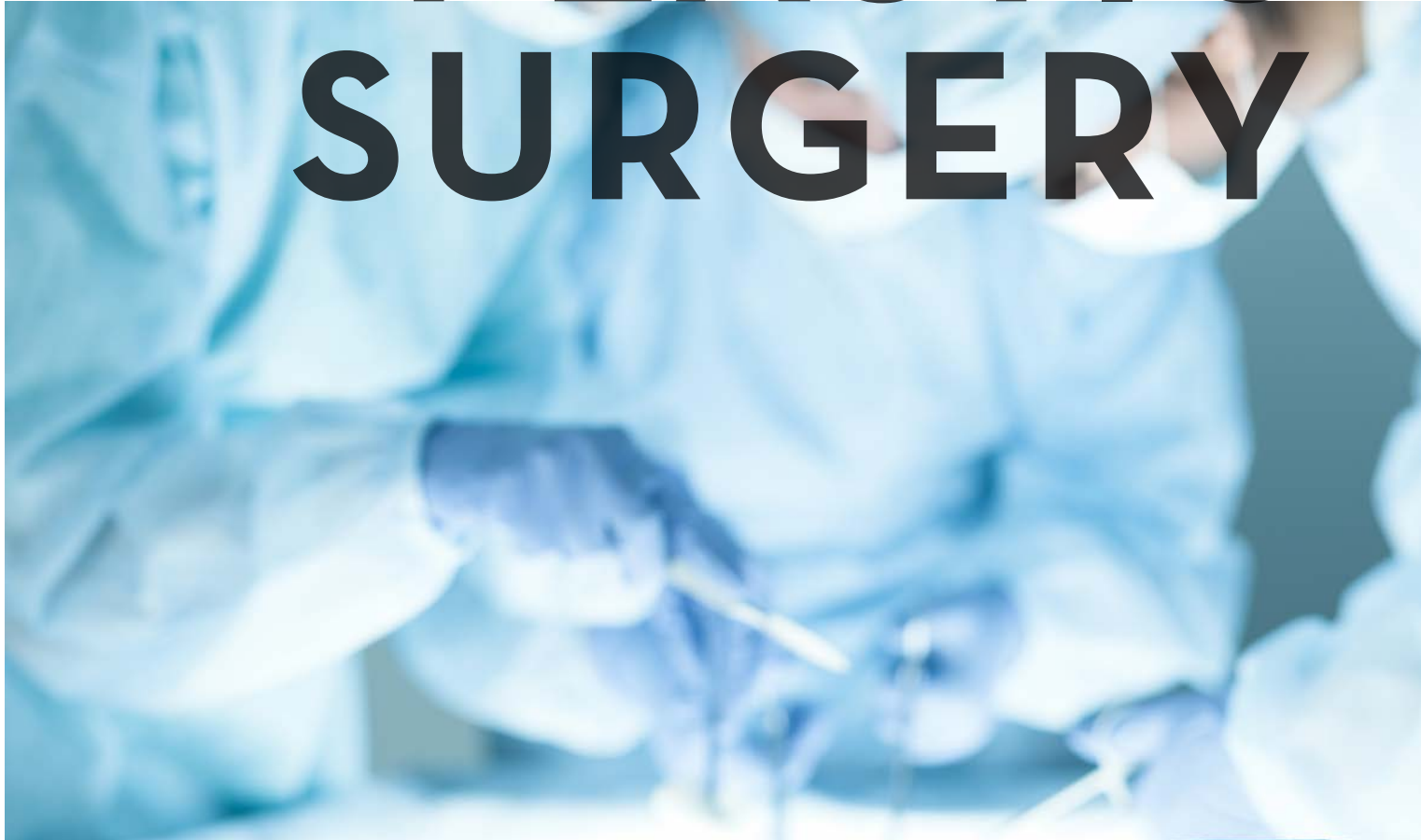Digitalization and ISAppS

Especially in the area of continuing education, we want to focus on many new digital possibilities and use new technical opportunities to bring further education home to you - without traveling - on demand. But also, our patients should learn to appreciate the advantages of being cared for by an ISAPS doctor. We have contracted a patient information system that informs and educates your patients fully automatically with information before and after the operation. Unbelievably exciting: our ISAppS.

New Fellowship Program

We also offer our junior staff many new opportunities: in addition to free membership for the duration of their residency, we now also offer additional free 3 and 6-month fellowship programs with selected experts around the world.

PLASTIC SURGERY



I am delighted that the fellowship program of the Dutch Association for Facial Plastic and Reconstructive Surgery, which has been successful for 12 years, was handed over to us by its founder, Dr. Jacques van der Meulen, for continuation in trusting hands. Intensive, free training in the field of aesthetics when it is most needed and financial resources are scarce. Interested? www.isapsresidentandsfellows.org

Member Recruitment

Are you interested in a free voucher for MedOne - our record-breaking e-learning platform? Tell your best colleagues about the benefits of ISAPS and recruit 5 new members. We will reward you with a free MedOne voucher for one year including 60 Top e-books, 1300 videos and super content. You are happy - we are happy.

ISAPS Olympiads

ISAPS World Congresses will now be held annually - in two formats. Our ISAPS World Congress continues every two years with an incredible amount of information in lectures

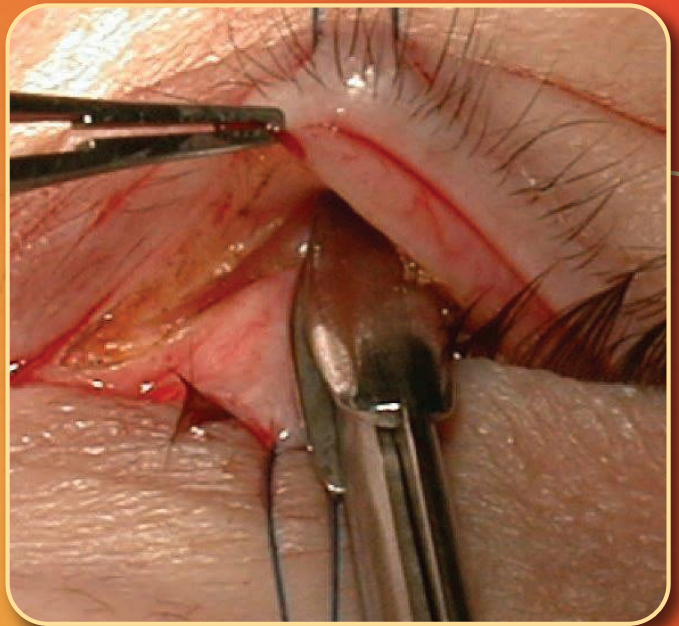
and Master Classes - next year for the 25th time in Vienna. And in the future, our new product: ISAPS Olympiads. We proclaim the Aesthetic Games: the best from all participating countries - 73 Global Alliance partners so far - will compete against each other in five aesthetic disciplines: face, nose, breast, body and non-invasive. The best presentations will win bronze, silver or gold on the podium. Save the date: September 2-4, 2021 - where? Athens, of course!

All exciting new projects.

Have fun reading.

Dirk F. Richter, MD
President

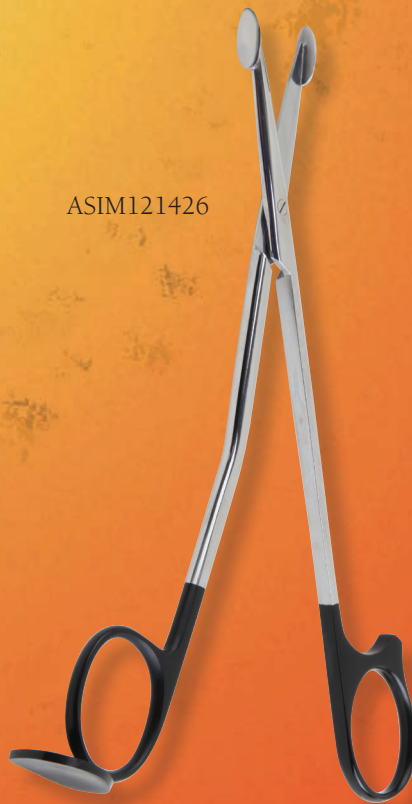Trepsat Facial Flap Dissector Scissors



Dissecting the lower eyelids.



ASIM121626



ASIM121426



ASIM121526

assi® 

ACCURATE SURGICAL & SCIENTIFIC INSTRUMENTS®

For diamond perfect performance™

accurate surgical & scientific instruments corporation

300 Shames Drive, Westbury, NY 11590

800.645.3569 516.333.2570 fax: 516.997.4948 west coast: 800.255.9378

Info: assi@accuratesurgical.com • Orders: orders@accuratesurgical.com

www.accuratesurgical.com



ISAPS GLOBAL ALLIANCE PARTICIPATING SOCIETIES

ARGENTINA
Sociedad Argentina de Cirugía Plástica Estética y Reparadora (SACPER)

AUSTRALIA
Australasian Society of Aesthetic Plastic Surgeons (ASAPS)

AUSTRIA
Österreichische Gesellschaft für Plastische, Ästhetische und Rekonstruktive Chirurgie (ÖGPÄRC)

AZERBAIJAN
Society of Plastic Surgery Azerbaijan (SPSA)

BELGIUM
Royal Belgian Society for Plastic Surgery (RBSPS)

BOLIVIA
Sociedad Boliviana de Cirugía Plástica Estética y Reparadora (SBCPER)

BRAZIL
Sociedade Brasileira de Cirurgia Plástica (SBPCP)

BULGARIA
Bulgarian Association of Plastic, Reconstructive and Aesthetic Surgery (BULAPRAS)

CANADA
Canadian Society for Aesthetic Plastic Surgery (CSAPS)

CHILE
Sociedad Chilena de Cirugía Plástica, Reconstructiva y Estética (SCCPRE)

CHINA
Chinese Society of Plastic Surgery (CSPS)

CHINESE TAIPEI
Taiwan Society of Plastic Surgery (TSPS)

COLOMBIA
Sociedad Colombiana de Cirugía Plástica, Estética y Reconstructiva (SCCP)

CYPRUS
Cyprus Society of Plastic, Reconstructive and Aesthetic Surgery (CySPRAS)

CZECH REPUBLIC
Czech Society of Aesthetic Surgery (CSAS)

CZECH REPUBLIC
Czech Society of Plastic Surgery (CSPS)

DENMARK
Dansk Selskab for Kosmetisk Plastikkirurgi (DSKP)

DOMINICAN REPUBLIC
Sociedad Dominicana de Cirugía Plástica Reconstructiva y Estética (SODOCIPRE)

EASAPS
European Association of Societies of Aesthetic Plastic Surgery (EASAPS)

ECUADOR
Sociedad Ecuatoriana de Cirugía Plástica, Reconstructiva y Estética (SECPRE)

EGYPT
Egyptian Society of Plastic and Reconstructive Surgeons (ESPRS)

FINLAND
Suomen Esteettiset Plastiikkirurgit ry. (SEP)

FRANCE
Société Française des Chirurgiens Esthétiques Plasticiens (SOFCEP)

GEORGIA
Georgian Society of Plastic Reconstructive and Aesthetic Surgery (GEOPRAS)

GERMANY
Vereinigung der Deutschen Aesthetisch Plastischen Chirurgen (VDÄPC)

GREECE
Hellenic Society of Plastic, Reconstructive and Aesthetic Surgery (HESPRAS)

HUNGARY
Hungarian Society for Plastic, Reconstructive and Aesthetic Surgery (HSPRAS)

INDIA
Indian Association of Aesthetic Plastic Surgeons (IAAPS)

INDONESIA
Indonesian Association of Plastic Reconstructive and Aesthetic Surgeons (InaPRAS)

IRAN
Iranian Society of Plastic and Aesthetic Surgeons (ISPAS)

IRELAND
Irish Association of Plastic Surgeons (IAPS)

ISAPS
International Society of Aesthetic Plastic Surgery (ISAPS)

ITALY
Associazione Italiana di Chirurgia Plastica Estetica (AICPE)

ITALY
Società Italiana di Chirurgia Plastica Ricostruttiva ed Estetica (SICPRE)

JAPAN
Japan Society of Aesthetic Plastic Surgery (JSAPS)

JORDAN
Jordanian Society for Plastic and Reconstructive Surgeons (JSPRS)

KUWAIT
Kuwait Society of Plastic Surgeons (KSPS)

LEBANON
Lebanese Society of Plastic, Reconstructive, and Aesthetic Surgery (LSPRAS)

MALAYSIA
Malaysian Association of Plastic, Aesthetic and Craniomaxillofacial Surgeons (MAPACS)

MEXICO
Asociación Mexicana de Cirugía Plástica Estética y Reconstructiva (AMCPER)

MOROCCO
Société Marocaine de Chirurgie Plastique Esthétique Plasticiens (SOMCEP)

NETHERLANDS
Nederlandse Vereniging voor Esthetische Plastische Chirurgie (NVEPC)

NORWAY
Norwegian Society of Aesthetic Plastic Surgery (NSAP)

OSAPS
Oriental Society of Aesthetic Plastic Surgery (OSAPS)

PAKISTAN
Pakistan Association of Plastic Surgeons (PAPS)

PANAMA
Asociación Panameña de Cirugía Plástica, Estética y Reconstructiva (APCPER)

PERU
Sociedad Peruana de Cirugía Plástica (SPCP)

PHILIPPINES
Philippine Association of Plastic, Reconstructive and Aesthetic Surgeons (PAPRAS)

PORTUGAL
Sociedade Portuguesa de Cirurgia Plástica Reconstructiva e Estética (SPCPRE)

ROMANIA
Romanian Aesthetic Surgery Society (RASS)

RUSSIA
Northeastern Society of Plastic and Reconstructive Surgeons (NESPRS)

RUSSIA
Russian Society of Plastic, Reconstructive and Aesthetic Surgery (RSPRAS)

SAUDI ARABIA
Saudi Plastic Surgery Care Society (SPSCS)

SERBIA
Serbian Society of Aesthetic Plastic Surgeons (SRBSAPS)

SERBIA
Serbian Society of Plastic, Reconstructive, and Aesthetic Surgery (SRBPRAS)

SINGAPORE
Singapore Association of Plastic Surgeons (SAPS)

SOUTH AFRICA
Association of Plastic, Reconstructive and Aesthetic Surgeons of Southern Africa (APRASSA)

SOUTH KOREA
Korean Society of Aesthetic Plastic Surgery (KSAPS)

SPAIN
Asociación Española de Cirugía Estética Plástica (AECEP)

SPAIN
Sociedad Española de Cirugía Plástica Reparadora y Estética (SECPRE)

SWEDEN
Svensk Förening för Estetisk Plastikkirurgi (SFEP)

SWITZERLAND
Schweizerische Gesellschaft für Ästhetische Chirurgie (SGAC)

SWITZERLAND
Swiss Society of Plastic, Reconstructive and Aesthetic Surgery (SSPRAS)

THAILAND
Society of Aesthetic Plastic Surgeons of Thailand (THSAPS)

TURKEY
Turkish Society of Aesthetic Plastic Surgery (TSAPS)

UKRAINE
Ukrainian Association of Plastic, Reconstructive and Aesthetic Surgeons (UAPRAS)

UKRAINE
Ukrainian Society of Aesthetic Plastic Surgeons (USAPS)

UNITED ARAB EMIRATES
Emirates Plastic Surgery Society (EPSS)

UNITED KINGDOM
British Association of Aesthetic Plastic Surgeons (BAAPS)

UNITED KINGDOM
United Kingdom Association of Aesthetic Plastic Surgeons (UKAAPS)

UNITED STATES
American Society for Aesthetic Plastic Surgery, Inc. (ASAPS)

VENEZUELA
Sociedad Venezolana de Cirugía Plástica, Reconstructiva, Estética y Maxilofacial (SVCPREM)

Vietnam
Vietnamese Society of Aesthetic and Plastic Surgery (VSAPS)

GLOBAL ALLIANCE



SPOTLIGHT ON JORDAN



RETIRED MAJ. GEN. DR. KHALDOUN HADDADIN, BSC, MB CHB, FRCS (ENG) - JORDAN

President, Jordanian Society of Plastic Reconstructive Surgeons

The Jordanian Society of Plastic and Reconstructive Surgeons (JSPRS) is a non-profit plastic surgery organization founded in 1988, under the umbrella of the Jordan Medical Association, with sixty active members today working in the Private Sector, Army, Government and University Hospitals and performing the full range of plastic surgery procedures including: Acute and Late Management of Burns, Hand and Microvascular Free Tissue Transfer, Head & Neck, Craniofacial, Breast and Post Bariatric Surgeries in addition to Aesthetic Invasive and Non-invasive Procedures.

The society represents all board-certified plastic surgeons in Jordan making JSPRS the sole authority for aesthetic and reconstructive plastic surgery in the country. JSPRS membership remains an exclusive privilege for plastic surgeons who possess the necessary qualifications. The Jordanian Board of Plastic Reconstructive Surgery certified by The Jordan Medical Council is an exam based certification for trainees who have completed an accredited Local or International Plastic Surgery Training Program and many plastic surgeons from the region regularly sit the exam. Our sixty members are board certified by the Jordan Medical Council, have precise focus in patient care, have comprehensive highly specialized training in aesthetic and reconstructive plastic surgery, and subscribe to the society code of ethics. Furthermore, a good number of JSPRS members are members of other well known international plastic surgery societies.

THE SOCIETY REPRESENTS ALL BOARD-CERTIFIED PLASTIC SURGEONS IN JORDAN MAKING JSPRS THE SOLE AUTHORITY FOR AESTHETIC AND RECONSTRUCTIVE PLASTIC SURGERY IN THE COUNTRY.

Jordan is a small country with limited resources, yet we have a great reputation in the Medical Arena in the Region. Jordan has been a safe haven for refugees from all over the Middle East, receiving thousands of injured patients from surrounding war stricken countries. Our plastic surgeons have been involved in rehabilitation of many of these patients in Jordan, particularly as facilities and capabilities for complex reconstructive surgery in these countries has been limited over the last few decades. In addition our plastic surgeons have been regular members of medical teams sent to these countries with field hospitals to assist in the humanitarian efforts.

Patient safety is a big concern for us and we encourage our members to follow and share all recent international guidelines and updates related to our specialty. One of the biggest difficulties facing our specialty over the last decade has been the increasing transgression by unqualified practitioners from other specialties performing plastic surgery operations under false pretences and with limited training.

We realize that this is not a unique problem to Jordan, and a concerted effort to limit these transgressions is on the forefront of our society's agenda both by official tracks as well as the dissipation of patient education by all available resources. We think a more global concerted effort by International Plastic Surgery Societies to highlight the problem may better reach a wider audience.

JSPRS ensures that its members have the highest standards of training, safe practice, and maintain the highest standards of ethical conducts and quality of care through continuous medical education: by holding conferences, symposia, workshops and lectures by the many distinguished visiting international speakers to our country frequently hosted by our society.

JSPRS is an active member of the Pan Arab Society of Plastic and Reconstructive Surgery and the International Confederation of Plastic Surgery Societies (ICOPLAST). We are honored to be affiliated with the prestigious ISAPS Global Alliance and we look forward to a fruitful cooperation for the benefit of our members and specialty.

GUESS WHO



CAN YOU IDENTIFY WHO IS IN THIS PHOTO?
ANSWER ON PAGE 72.

ISAPS WOULD LIKE
TO OFFICIALLY
THANK AND
ACKNOWLEDGE THE
GENEROUS SUPPORT
OF OUR GLOBAL
SPONSORS

ISAPS
PREMIER
GLOBAL SPONSOR
PROGRAM

ISAPS GLOBAL SPONSOR PLATINUM

PLATINUM Sponsor:

POLYTECH

MERZ
NORTH AMERICA

ISAPS GLOBAL SPONSOR GOLD

GOLD Sponsor:

GC Aesthetics™

EDUCATION COUNCIL UPDATE



VAKIS KONTOES, MD, PHD - GREECE
Chair, ISAPS Education Council

On April 15-16, a Visiting Professor Program (VPP) took place at the University of Alexandria, Egypt followed by the ISAPS Course - Egypt held in Cairo on April 18-19. Both events were extremely successful. The VPP was held in the University Hospital of Alexandria, in the Department of Plastic Surgery, with Dr. Apostolos Mandrekas from Greece and me as the Visiting Professors.

An extended program of surgeries including facelift, rhinoplasties, and blepharoplasties was followed by detailed talks on each of these procedures. On the first day, more than 20 residents attended a face lift and blepharoplasty on different patients in the OR followed by a phenol peel on another patient. After the surgeries, presentations took place in the department's amphitheater that were also attended by the consultants and specialists of the department. On the second day, the residents and specialists attended two rhinoplasties that demonstrated step-by-step procedures and solved many of their queries about these techniques during the presentations that followed the surgery.

The Education Council wishes to thank Dr. Renato Saltz, Chairman of the VPP, for his cooperation and approval, Dr. Naser Ghozlan, the Head of the Plastic Surgery Department in the University of Alexandria, and Dr. Hussein Abulhassan, National Secretary for Egypt, for their support and excellent organization of this VPP that offered a lot of benefits to the Residents. The feedback was superb and more information can be found in the detailed report in this edition of *ISAPS News*.

Following this very successful VPP, we moved to Cairo where the ISAPS Course-Egypt, was held in the outstanding Marriott Mena resort near the pyramids. The faculty including Nazim Cerkes (Turkey), Constantin Stan (Romania), Michel Rouif (France), Luiz Toledo (UAE), Manoj Khanna (India), Cemal Cenyuva (Turkey), Apostolos Mandrekas (Greece) and me had the opportunity to join with the local speakers, before a full room of 365 participants to present the hottest topics in aesthetic plastic surgery. Talks, round tables, debates, workshops and wonderful social events outlined the absolute success of one of the most interesting ISAPS Courses in recent years. Our sincere thanks to Drs. Abulhassan and Hisham El-Minawi, Assistant National Secretary for Egypt, for this outstanding and very well organized ISAPS educational event.

ISAPS Second Vice President Dr. Gianluca Campiglio was also a Visiting Professor in April in Hungary. His full report can be found elsewhere in this issue of *ISAPS News*.

Seven ISAPS-endorsed educational events took place through March and April with ISAPS being present internationally and supporting our mission of *Aesthetic Education Worldwide®* in Panama, the UK, Spain, Italy, Germany, Ukraine, and France.

Three successful webinars were presented: Enrico Robotti (Italy) on Primary Rhinoplasty and Wolfgang Gubisch (Germany) on Secondary Rhinoplasty on March 7 from Istanbul; Dirk Richter (Germany) on Revisional Ectropion Correction and Giovanni Botti (Italy) on Complex Lower Lid Revision Surgery from Stuttgart on April 12; and Tunc Tiryaki (Turkey) on Stem Cell Assisted Facial Rejuvenation with Micro-filling from Istanbul on May 4. These webinars are provided free of charge for Resident and Fellow members and for Eco+ Associate and Eco+, Business and First members.

Additional programs scheduled include an ISAPS Course in St. Petersburg, the 2nd module of an ISAPS F.A.S.T. program on Breast in Moscow, and seven ISAPS endorsed meetings worldwide. More information can be found in our website in the calendar of events link.

Many more educational events are already scheduled through the end of this year including three Courses, four Symposia, one final ISAPS F.A.S.T. module, many endorsed meetings, and several more are pending approval by the Education Council about which we will inform you in our next report.

Our sincere thanks to all of you for supporting our ISAPS Education Mission from any position in the ISAPS family. We urge you to keep in close contact with us for any matter regarding educational issues in aesthetic surgery. We will be very happy to support and help your initiatives.

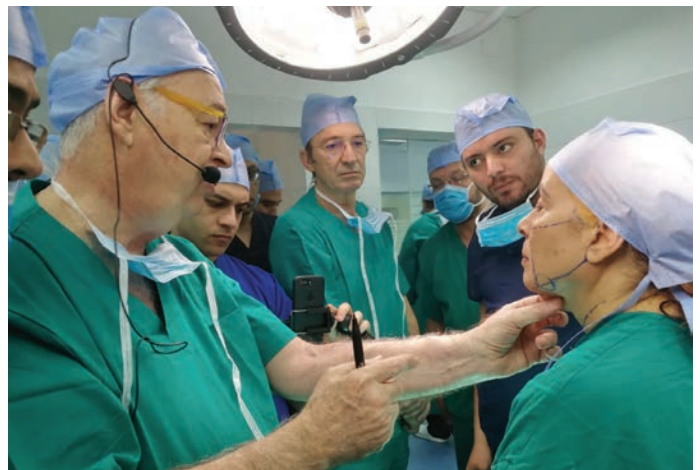

Figure 1 - Marking of patients before surgery during the VPP in Alexandria.



Figure 2 - Group photo of the ISAPS and local faculty with participants of the ISAPS Course in Cairo at Marriott Mena resort with the pyramids in the background.

ICAMPS

PASSION AND COLD CALCULUS OF PLASTIC SURGERY



PAVLO DENYSHCHUK, PHD, MD - UKRAINE
ICAMPS Founder

ICAMPS#2, an event that was unusual for medical congresses, was held in Kiev in the style of Tango on March 22-23. Why tango? Only a passion for his craft allows the surgeon to learn and work throughout all his life. This is the second International Congress for Plastic Surgeons and Aesthetic Medicine Specialists (ICAMPS) endorsed by ISAPS.

The event gathered more than 200 plastic surgeons and 100 specialists of aesthetic medicine from 17 countries who came to Kiev to learn modern methods of facial rejuvenation and nose correction. Two parallel sessions were held for plastic surgeons and aesthetic medicine specialists that included four live surgeries and five master classes in injection and hardware methods. Live communication among related professionals and the experience exchange is of vital importance.

Within the framework of the congress, such specialists as ISAPS President Dirk Richter and Heike Heise (Germany); Guy Magalon, Pierre Akkerman and Mihai Gorj (France); Pierre Quinodoz (Switzerland); Jamie Calderon (Mexico); Nuri Celik (Turkey); Stefano Verardi, Laura Balint, Paolo Rovatti and Giorgio Maulo (Italy); Enoc Chambi (USA); Marlen Sulamanidze (Georgia) and others shared their experiences.



Figure 1 - ICAMPS founder, Dr. Pavlo Denyshchuk, presents a plaque to ISAPS President, Dr. Dirk Richter.



Figure 2 - Tango dancers at the gala dinner.

The Tango theme continued at the gala-dinner where guests enjoyed the evening that featured a lively dance performance of passion and freedom.

For four years now, Kiev has united doctors of aesthetic medicine from different parts of the world. ICAMPS#2 is the fifth educational event for plastic surgeons under the auspices of ISAPS.

During 2016-2017, three Visiting Professor Programs (VPP) took place here with the participation of such masters of plastic surgery as Alan Fogli, Alex Varpaele, Oscar Ramirez, Constantino Mendieta and others. The good tradition of the VPP was continued by the newly created ICAMPS congress in 2018 that brought specialists of plastic surgery and aesthetic medicine together in one event.



Figure 3 - More than 200 plastic surgeons and 100 specialists of aesthetic medicine from 17 countries came to Kiev.

ISAPS VISITING PROFESSOR PROGRAM

INDIA



THOMAS BIGGS, MD - UNITED STATES
ISAPS Past President

It was my pleasure to serve as a Visiting Professor for the Residents at Nair Chari Charitable Hospital in Mumbai, India on the 13th of March. I was also scheduled to teach them the morning of the 14th, but that was cancelled because most of them were going that week to the Indian Society of Aesthetic Plastic Surgery meeting at which I was one of the principal speakers.

There were forty attendees including Residents from three different programs. Despite the reduced time, I was able to give four lectures:

- 1) *What is Aesthetic Surgery* in which I included a discussion regarding the first consultation and another about how and why to teach.
- 2) *Evolution of the Breast Implant*
- 3) *How to Give a Presentation*
- 4) *Sixty Years in Plastic Surgery: What I've Learned*

The next day I traveled to Lonavalo, a city forty miles south of Mumbai, for the Aesthetic Surgery meeting where I gave three lectures:

- 1) *Fundamentals of Aesthetic Surgery*
- 2) *The Magic of Fat Grafting: How to Make It Work*
- 3) *Sixty Years in Plastic Surgery: What I've Learned*

I found the Residents well informed and very eager to hear what I had to say. The reason I went to India was for the teaching of the Residents, and I emphasized this in my lectures in Lonavalo. With 350 attendees, the meeting was judged as the largest plastic surgery meeting in India's history and most of those people attended all my lectures.

Neeta Patel is the President of the Indian Society for Aesthetic Plastic Surgery. In her introduction, she stated, "Dr. Biggs is the person who brought aesthetic surgery to India." I started visiting India in 2004 as a speaker at an ISAPS course. At that meeting, Dr. Patel told me that no one in India had any training in aesthetic surgery and how much she wanted to know more. I responded that given an airline ticket and a hotel room, I would come and tell her all I knew. She asked if she could invite some friends and of course I said, "absolutely" and that gave birth to an annual symposium in Mumbai that lasted for many years. As it grew, I invited more and more speakers and we always did several live surgeries.

Among the people I met in 2004 was Satish Arolkar. I have maintained a close relationship with him since that time. It was he who invited me and organized this visit.



Figure 1 - Dr. Biggs with Dr. Neeta Patel.

It was a pleasure and an honor to serve as a Visiting Professor and I was proud to claim to the residents that: *ISAPS is where the world and new ideas in plastic surgery come together.*



Figure 2 - Dr. Biggs with Dr. Satish Arolkar.

ISAPS VISITING PROFESSOR PROGRAM

HUNGARY 2019



GIANLUCA CAMPIGLIO, MD, PHD - ITALY
ISAPS Second Vice President

From April 11 to April 13, I was an ISAPS Visiting Professor in Hungary at the invitation of the Hungarian Society of Plastic, Reconstructive and Aesthetic Surgery (HSPRAS). This program, the first in this country, was very well organized by the President of the Society, Prof. Janos Varga, and the ISAPS National Secretary, Dr. Csaba Molnar. Szeged, the third largest city in Hungary and seat of one of the most prestigious and old universities, hosted this event.

I arrived on the evening of April 10th in Szeged and had a lovely dinner with Prof. Varga, Dr. Molnar, their wives and their two sons, both involved in two different residency programs in plastic surgery. Every time that I visit a country as an ISAPS Visiting Professor, I am curious to learn about the local training program in plastic surgery and I always discover interesting things. For example, I did not know that the system of selection in Hungary is very hard because every year the number of places for residents is decided according



Figure 1 - Together with the hosts of the first VPP in Hungary: Csaba Molnar, ISAPS National Secretary for Hungary, (left) and Prof. Janos Varga, President of HSPRAS, (right).

to the necessity in the country so it is possible that for one or two years there are no available places for new residents in plastic surgery. Prof. Varga also explained to me that practicing aesthetic plastic surgery is strictly ruled by the government so that young plastic surgeons, once they have completed their residency, cannot operate alone for a five-year period, but must practice under the supervision of an elder plastic surgeon. Even the practice of aesthetic surgery in general is different from many other countries I have visited as it is reserved for board certified plastic surgeons. Of course, we also discussed many other pleasant subjects such as the long Hungarian history and the great role of this country in Europe in past centuries.



Figure 2 - Together with Prof. Janos Varga and his son Akos, a young resident in plastic surgery with whom we discussed a lot about the mission of ISAPS for the younger generations.

The next day, at the conference room of the Szeged University, from 09.00 to 17.00, I gave ten multimedia lectures, with drawings and videos, on the main aesthetic surgical procedures of the face, breast and body. The audience included residents and plastic surgeons coming from all over Hungary. Each presentation was followed by questions and comments in a very interactive way. Prof. Varga told me during lunch that the practical approach of my lectures was very much appreciated, especially by the younger surgeons.

After the conference, Prof. Varga showed me his department at the University Hospital and introduced me the two patients ready for the live surgery on the following day: a middle-aged lady with secondary soft tissue ptosis

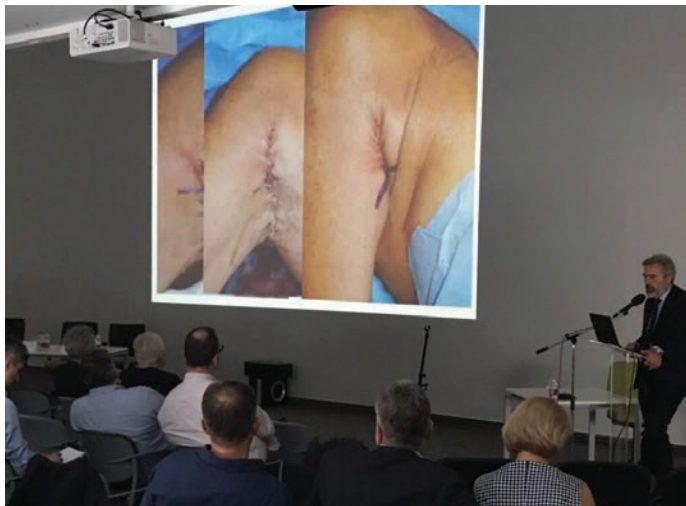

Figure 3 - During the day of lectures at the University of Szeged before an audience HSPRAS members, young plastic surgeons, residents and students.

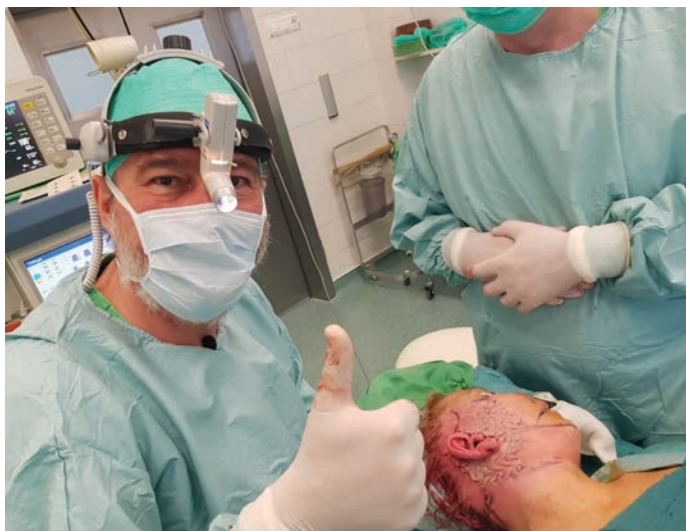

Figure 4 - The day of the live surgeries at the end of a secondary face and neck lift with hemostatic net.

of the cheeks and neck and a young girl with a severe asymmetric breast hypertrophy (gigantomastia). I marked the breast reduction patient explaining to Prof. Varga and his staff how I decide the new position of the nipple areola complex and how I select the glandular pedicle in this type of case. Being a severe ptosis, I preferred the supero-medial technique as the superior one requires a folding of the pedicle that can jeopardize the venous drainage of the areola and lead to its sloughing or true necrosis.

A very pleasant dinner in a traditional fish restaurant on the bank of the Tisza, the local river tributary of the Danube, concluded this long but very positive day. As the ISAPS Second Vice President, I had the opportunity to illustrate to the board members of the Hungarian Society our vision for the next two years, including the importance of joining the ISAPS Global Alliance.

Friday April 12 was dedicated to the live surgeries that started early at the University Hospital. I met the anesthesiologists and the surgical nurses to whom I illustrated my simple necessities during the procedures. The operations were live streamed to the auditorium where the participants could pose questions and ask for clarifications. In the first procedure, I performed a secondary face and neck lift with SMAS flap. At the end of the operation, I showed the use of the hemostatic net, conceived by Brazilian plastic surgeon Andre Auersvald, that I now use routinely and consider one of the real recent innovations in the field of aesthetic surgery. Obviously, the use of multiple transcutaneous stitches in the cheeks and neck generated a lot of questions in the audience especially about its safety and the risk of permanent marks. I explained that there is no danger if the stitches are removed no later than 48 hours. Honestly, I leave those in the mastoid area 24 hours longer to avoid the possibility of a late seroma or hematoma. With the second operation, I illustrated the supero-medial pedicle technique that in my opinion took the place of the inferior pedicle procedure as an "all seasons technique." It provides a long-term, better and more reliable aesthetic result with no risk of bottoming out with the same guarantee of safety even in challenging cases like the one of my surgery.

Continued on page 16

At the end of the live surgeries, Prof. Varga introduced me to Prof. Kemeny, head of the Dermatology Department. As happens frequently in eastern European countries, plastic surgery divisions are part of a Dermatology Department where all the skin problems, from burns to pemphigo, are treated. Prof. Kemeny and Prof. Varga guided me to visit the modern laboratories of the department, all GMP approved, for research and clinical applications of stem cells. This experience really touched me as it reminded me of the same situation of Niguarda Hospital, the large hospital in Milan where I did my residency and got my PhD in stem cells.

The nice experience in Szeged terminated with a very pleasant dinner in a local winery where I had the opportunity to appreciate wines and meals from various regions of Hungary.

On Saturday 13, early in the morning, I was accompanied to the castle of Godollo, an ancient building totally renovated, where an official meeting of the Hungarian Society of Aesthetic Plastic Surgery was planned. Dr. Molnar, ISAPS National Secretary for Hungary, made a presentation about ISAPS to the participants and explained the new membership policy including the many benefits of joining the society. Subsequently, I gave a 90-minute keynote lecture on breast augmentation presenting my personal point of view on most of its technical aspects such as approaches, plane of the pocket and type of implant. As a member of the ISAPS task force on breast implant safety, I also illustrated the current state of BI-ALCL and BII, reporting the official position of ISAPS about the recent ban of some textured implants in France. After lunch, I was driven to Budapest and flew back to Italy. The same evening, I was pleasantly informed that my proposal to join the Global Alliance was discussed by the Hungarian board and finally approved so that Hungary became its 70th member.



Figure 5 - Meeting with Prof. Varga and Prof. Kemeny, head of Dermatology Department of the University Hospital of Szeged, talking about the importance of stem cells and regenerative medicine.

ISAPS VISITING PROFESSOR PROGRAM

ALEXANDRIA, EGYPT



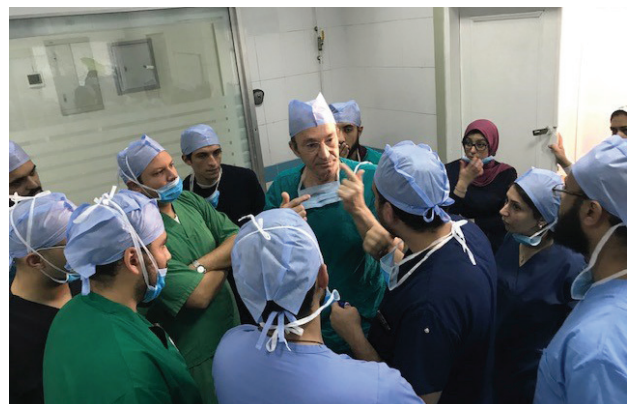HUSSEIN ABULHASSAN, MD - EGYPT
ISAPS National Secretary for Egypt

On April 25th, we had the honor and pleasure of having both Drs. Vakis Kontoes and Apostolos Mandrekas from Greece as our Visiting Professors in the Plastic Surgery Department at Alexandria University, Egypt. The two professors spent two days with our residents and fellows along with the faculty of the department as they lectured on blepharoplasty techniques, face lift, and both open and closed rhinoplasty.

After seventeen case examinations and presentations by the residents, six cases were selected for operation demonstrations. Blepharoplasty, face lift, and open and closed rhinoplasty were nicely demonstrated and finally Dr. Mandrekas performed a case of phenol chemical peeling having brought the phenol with him from Greece. The operative sessions were transmitted to the amphitheater where all visitors and about forty residents attended. Involvement of the attending group with the professors was amazing and very advantageous - and will encourage us to start other programs in other universities in Egypt.

Even through the scientific part of the visit was overwhelming, we nevertheless planned sightseeing visits of the Greek area of Alexandria which is part of the city's history, including the Biblioteca Alexandrina in the same place of the Old Great Alexandria Library, the house of the great Greek poet Kavafis in the old part of the city, and the Great Patriarchy Church.

An excellent dinner with the department faculty ended the visit - an outstanding experience for our residents and fellows in Alexandria. Our thanks Vakis and Apostolos for their support.



US FDA BREAST IMPLANT RISK/ BENEFIT HEARING

WASHINGTON, DC



MARK JEWELL, MD - UNITED STATES

ISAPS was represented at the US FDA CDRH hearing on March 26-27 in Washington, DC by Nina Naidu, MD, the ISAPS National Secretary for the United States. ASAPS and ASPS also sent official representatives. There were approximately 25 plastic surgeons who used the public comment session to present input to the FDA.



The FDA panel of experts discussed the risk/benefit of breast implants, Breast Implant Associated Anaplastic Large Cell Lymphoma (BIA-ALCL), Breast Implant Illness (BII), imaging to detect silent rupture, texture, informed consent, breast implant illness, and the use of Acellular Dermal Matrix (ADM)/absorbable mesh. The topic of post-approval studies and implant registry were discussed. There were two plastic surgeons on the panel who helped other panel members understand the risk/benefits of breast implants.

Breast Implant Illness Symptoms (Patients with breast implants attribute the following symptoms to being caused by breast implants.)

- Nervous system: Brain fog, memory loss, migraines, tinnitus, neuralgia/burning pain
- Musculoskeletal: Muscle/joint pain, sore and aching joints, numbness/tingling in upper and lower limbs, fibromyalgia
- Immune/inflammatory Autoimmune disease: Raynauds, Hashimotos, RA, scleroderma, Lupus, Sjogrens
- Infections: fevers night sweats, slow healing and easy bruising, chronic fatigue, sudden food intolerance and allergies, tender lymph nodes
- GI/genitourinary: Frequent urination, liver and kidney problems, reflux, gastritis, leaky gut, irritable bowel syndrome
- Integument: Hair loss, dry skin, dry hair, skin rashes
- Psychological: Anxiety, depression, panic attacks, sleep disturbance
- Cardiorespiratory: Shortness of breath, heart palpitations, arrhythmia, heart pain, cough, throat clearing

BIA-ALCL Symptoms include:

- Acute, painful swelling on one side from a fluid collection around the implant that occurs years after implant surgery (late-term seroma).
- Fluid accumulation can occur for a variety of reasons, including BIA-ALCL. Perform an ultrasound-guided fluid aspiration for laboratory analysis (cytology, bacterial culture, and immunohistochemistry).

- Laboratory testing of the fluid will determine if the rare BIA-ALCL is present (histology, and immunohistochemistry for CD 30-positive and ALK-negative T- cell lymphocytes).
- This Breast Lymphoma is not classified as breast cancer, according to the WHO, but as a cancer of the lymphatic system located at the breast with very good treatment options. 85% of BIA-ALCL is in the seroma fluid, 15% may be seen as capsular masses.
- Surgery to remove implant and capsule is the best treatment for BIA-ALCL
- Early diagnosis and treatment is essential for best outcomes. Brentuximab is considered the drug of choice for treating BIA-ALCL (not available in all countries). Chemotherapy regimens such as CHOP (cyclophosphamide, doxorubicin, vincristine, and prednisone) may carry a higher risk of morbidity when treating BIA-ALCL.

Allergan, Mentor, Sientra, and Ideal Implant also made presentations to the FDA. To date, there does not appear to be a single BIA-ALCL case where the patient has had smooth-surface implants. BIA-ALCL is associated with textured-surface implants from Allergan, Sientra, and Mentor that are approved for sale in the USA. The manufacturers cited poor follow-up on the recommended MRI studies to detect silent rupture of gel implants largely due to patient expense.

Additionally, the panel heard comments from women who had developed BIA-ALCL and BII. Their comments were largely negative towards breast implants and the manufacturers.

In May, 2019, the US FDA CDRH indicated that the approved macrotecture known as BioCell (Allergan) along with other approved textured surface implants/tissue expanders would be allowed to be sold in the US. The FDA states that regulatory action must be based on scientific data. Following the advisory hearing, the FDA does not believe that, on the basis of all available data and information, the device meets the banning standard set forth in the Federal Food, Drug and Cosmetic Act. In 2018, textured breast implants represented less than 10% of breast implants sold in the U.S.

It is expected that the US FDA CDRH will issue new guidance instructions regarding the use of textured surface implants and tissue expanders. This would consist of “Black Box Warning” (an alert that a drug or device has specific greater levels of risk of adverse events associated with its use), informed consent instructions and a checklist regarding the use of textured surface implants/tissue expanders.

BIA-ALCL Data Update


Mark W. Clemens, MD – United States

There are currently 477 unique confirmed cases of BIA-ALCL outside of the United States. So far, we have been able to confirm 164 US cases. In the US, 282 unique cases have been reported to the PROFILE registry and confirmation is ongoing. Therefore, there are approximately 641 unique confirmed cases worldwide and there are 21 total deaths worldwide which includes 5 US deaths, directly attributable to disease.

There have been 4 new deaths reported in the past eight weeks from Australia, Canada (May 28th), Italy, and Argentina emphasizing that this is a lymphoma and a malignancy, and therefore not benign at any stage. Out of concern for BIA-ALCL, Allergan BioCell textured implants now have sales restriction in 39 countries including Europe, Israel, Russia, Singapore, Colombia, Canada, and South Africa. Importantly, no country worldwide recommends explantation or has considered or implemented a ban on “texturing.”

FEATURE

APPLE WORM



ASKO SALMI, MD, PHD - FINLAND

Think about a tiny, happy apple worm creeping along on a small apple. A nice, sweet and delicious apple. Jogging around.



Not worrying. Maybe a nice home hole somewhere in the apple. Worm's whole universe is the apple. There is nothing more than the apple. External world does not exist because our worm is not capable of imagining anything else than its small, limited apple. Emptiness around the apple does not

bother it because the external world does not exist in our worm's brain and even though it has some idea that there must be other apples (among other things) it is not capable of thinking such things. Its understanding and knowledge is limited and blocked.

The idea of not understanding the bigger picture was introduced by professor of cosmology Esko Valtaoja years ago. He used this idea to describe human beings' limited resources to understand the universe. The odd behavior of small particles - quarks - does not make any sense to human beings, nor do the vast universe, parallel universes, black holes and so on. Maybe we are like apple worms that have no capability to understand everything that exists in the universe. It is also possible that we are living without knowing what is right next to us. Our senses, mind and technology are limited and blocked.

What has this to do with plastic surgery? Nothing at all and everything. Maybe we are quite often like apple worms creeping on our apples.

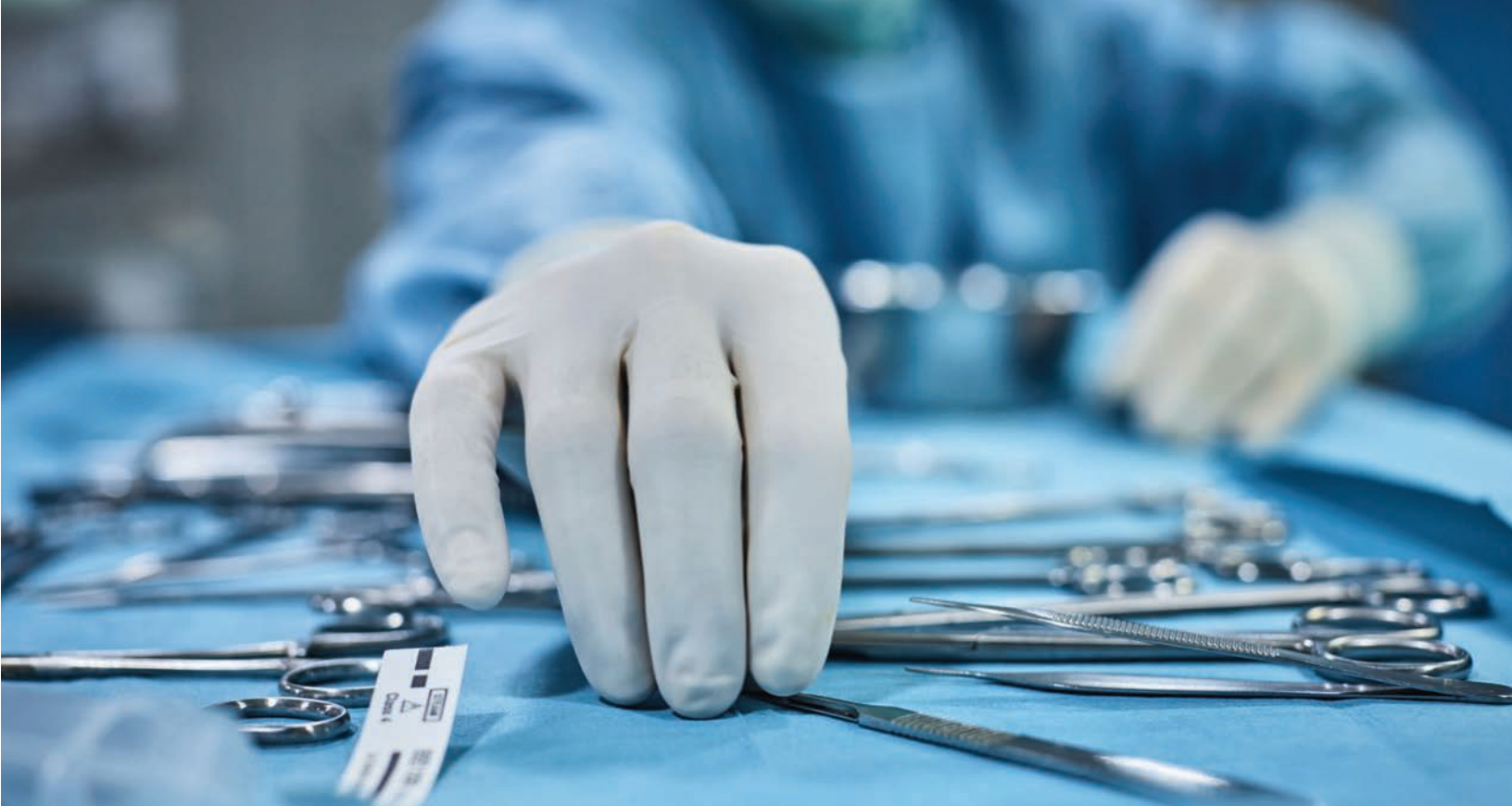It's not unusual that we have old traditions and habits in operating theaters. We are doing things the same way over and over again. Tens of years. Never stopping. Always jogging around the apple. Happy with everything. Never stopping to think if things could be done another way or even a better way? Is this the best we can achieve? Top work? Excellence in all respects?

Routines are necessary and good, but not all of them. Every now and then things should be checked and updated. New data, new science, new knowledge, new innovations have to change our routines and ways of thinking and working. However, a change with caution; new is not always a synonym for good. A change always has to lead to our patients' wellbeing.

The second problem is a little bit more difficult. Maybe a worm cannot understand the external world because of its own limited resources. A fact that leads to an isolated non-changing status. The same status can also be the result of indifference - of not caring. Everything is fine if I'm fine. The universe shrinks around you. Me and me doing well. Limited resources - whatever they are - leading to a limited universe are forgivable, but indifference is not.

Indifference can occur as neglecting professional education and skills, neglecting indications for treatments and operations, not caring about proper diagnosis, medication or just being content with the average.

Plastic surgery, like everything else, is a complicated universe or network where everybody involved is needed and as important as any other hub in that network. The system does not work if one of the hubs is missing or malfunctioning.



Surgery is always teamwork, and your team is only as good or as strong as its weakest link. Therefore, there is no room for missing or malfunctioning links. Being content with average can also result in a very weak chain.

I woke up from my worm's sleep in 2004. I had done years of abdominoplasties as I was taught to do them and after surgery aspirated numerous seromas as assumed. Bleeding during surgery was constant and transfusions not rare. Wound complications. Infections. And so on. In one word: bad surgery. Over ten years I had been like a worm; happy with surgeries because complications were inevitable and results were not worse than what my colleagues had. Average thinking.

Fifteen years ago, my worm's life ended. I noticed that there were ways to improve results, avoid complications and promote healing. There were quilting sutures to send seromas to history and lidocaine adrenalin infiltration to reduce bleeding. Combining these two ideas led to a technique with no seromas, no drains, no severe complications.

A few years later, I had a second awakening: there seemed to be some "bugs" in breast implant capsules and there was a way to get rid of them. Maybe by combining these ideas we could prevent capsular contracture after breast augmentation? Indeed it worked. Capsular contracture after triple antibiotic irrigation is very rare. Focusing on a common problem led to a breakthrough in treatment.

To make progress means that you must have interest in your work and also thrive for perfection. Bad must be replaced by good; good will do for some time, but excellence is our ultimate goal. Contentment with average is indifference. Worm's life.

Plastic surgery is not quantum physics and there is always a better solution as long as we recognize our problems and are willing to solve them. There is no place for indifference or a worm's life.

HUMANITARIAN

Humanitarian Programs with openings for ISAPS members are listed on our website under Medical Professionals. We add new programs as we receive information. The newest addition is included here.

CHEIRA (Switzerland) - Humanitarian plastic surgery mainly in children in West Africa (Burkina Faso, Mali, Sierra Leone)

www.cheira.org

Contact: Dr. Jan G. Poëll, Schonbuel 8, CH 9402 Morschwil, Switzerland, jpoell@bluwin.ch

Locations and dates: We are planning two missions this year in Burkina Faso in autumn, one in Ouahigouya and one in Léo and one in May in Mali, Bamaco. Next year two missions in Ouahigouya (Persis), the first in January (hand surgery) and one in November plastic surgery and paediatric surgery, mainly hernias, are planned and two, spring and autumn in Léo, reconstructive plastic surgery.

Specific surgical need: cleft lip, tumours, burns, especially hands.

Number of surgeons needed: one surgeon or resident per mission

NEW ISAPS BOOTH PREMIERED AT ASAPS MEETING – NEW ORLEANS – MAY 18-21



COMMITTEE REPORT

RESIDENTS AND FELLOWS



MARIA WIEDNER, MD - GERMANY
Chair, Residents and Fellows Committee

It is a great pleasure for me to report the latest developments of the ISAPS Residents and Fellows Committee over the last months.

First, we are very happy to present our new ISAPS Fellowship program! After many years of fruitful cooperation with the successful fellowship, Dutch Association for Facial Plastic and Reconstructive Surgery (DAFPRS), founded in 2006 and led by Dr. Jacques van der Meulen (Netherlands), we have taken over this program under the umbrella of our society. We are now able to offer over fifty fellowships in thirteen different units every year. Each of these fellowship programs is scheduled for three months. The registration deadline for 2020 has just expired and we are now working intensively on the selection and organization process. We have already added more units for 2021, making the offer even greater. Check them out! www.isapsresidentsandfellows.org

At our next World Congress in Vienna on September 2-5, 2020, the free paper sessions will give fellows the opportunity to win a travel scholarship for these ISAPS fellowships worth \$1,000 each. The best scientific work presented in these sessions will be rewarded! Share this information with all young talents and motivate them to participate. Find information about the next ISAPS World Congress already at www.isapsvienna2020.com.

Another wonderful innovation is our first Residents and Fellows Congress, which will be held in Bruges, Belgium on October 17, 2019. This will be a unique opportunity,

especially for young colleagues, to learn first-hand from the aesthetic plastic surgery experts both surgical tips and tricks as well as office management and legal matters.

Our Secretary, Dr. Ivar van Heijningen (Belgium), who is also the current President of the European Association of Societies of Aesthetic Plastic Surgery (EASAPS), is organizing this special opportunity in advance of this year's EASAPS Biennial Meeting, which attracts more experienced colleagues. I would like to invite them, too, if they do not yet have an established practice, to participate in our Residents and Fellows Congress - especially the second part, with intensive lectures on the basics of aesthetic surgery, that will be of particular interest here.

The meeting is open to everyone, although we especially want to address colleagues in training. As a thrilling start in the morning, master classes on non-invasive therapies will also be available. After a brief welcome, a wide range of relevant topics will be covered, from patient guidance and documentation to marketing. In the afternoon, there will be intensive lectures of twenty minutes each on the most important aesthetic operations from head to toe. At the end of the day, everyone should go home with many new ideas and guidelines for aesthetic plastic surgery practice. You can see the program and more information for both events at www.easaps.org.

Please pass this information on to all colleagues in training who do not yet have their own ISAPS access!

And don't forget! For all residents enrolled in an official plastic surgery training program, membership in our society is free because we know that at this time, the need for education is greatest and the budget is smallest.

NATIONAL SECRETARIES

CHAIR'S REPORT



MICHEL ROUIF, MD - FRANCE
ISAPS National Secretaries Chair

A new term has begun with 108 National Secretaries (NS) or Assistant National Secretaries (ANS) who are all highly motivated to help grow ISAPS which for several years has continued an expansion based on two fundamentals: Education and Patient Safety. This quality approach is essential to strengthen the role of cosmetic surgery, a specialty in its own right with its specificities, particularly in the care of patients. Each continent, each country has its own structures, its legislation, its training courses. Without standardizing, but always seeking to elevate the whole practice toward greater excellence, the entire network of National Secretaries is a very strong and direct link with the Board of ISAPS. They can help you to quickly get the information you need. If you do not know your National Secretary, simply go to: <https://www.isaps.org/medical-professionals/isaps-organization/national-secretaries/>.

The October 2018 Congress in Miami Beach was an opportunity to energize our hard-working National Secretaries who met for a full day before the Congress began to discuss many aspects of their responsibilities. Thank you to everyone involved in this tremendous network. They are your voice. They can support your course endorsement application, or help you with special projects such as organizing an ISAPS Course or Symposium in your country.

Every ISAPS member is an ambassador in his region and initiatives with your National Secretary are welcome. Each member should find appealing benefits in the various categories. It is this dynamic that needs strengthening today. Becoming an ISAPS member means promoting a practice that seeks the best of knowledge and patient safety.

Go to <https://www.isapsmembership.org/benefits> to understand the fantastic and varied opportunities offered to everyone in terms of education and communication, but also meeting new ways of understanding our magnificent specialty through international meetings.

Many National Secretary elections were held this spring bringing new people to our community in order to represent and serve ISAPS and the colleagues of their countries.



The National Secretaries at their meeting in Miami Beach on October 30. Photos courtesy of Alexander Kutubidze, National Secretary for Georgia.

I would like to congratulate the following members:

New National Secretaries (NS) and Assistant National Secretaries (ANS)

Heike Klepetko (Austria) – NS
Kaarlo Ståhlberg (Finland) – NS
George Li (Hong Kong) – NS
Amer Al Mansory (Iraq) – NS
Francesca de Angelis (Southern Italy) – ANS
Andrea Margara (Northern Italy) – ANS
Mazen Bdour (Jordan) – NS
Souad Terab (Morocco) – NS
Berend van der Lai (Netherlands) – NS
Argentina Vidrascu (Romania) – NS
Dmitry Melnikov (Russian Federation) – ANS
Woffles Wu (Singapore) – NS
Naveen Cavale (UK) – NS
Mo Akhavan (UK) – ANS

Re-elected National Secretaries (NS) and Assistant National Secretaries (ANS)

Vladimir Marik (Czech Republic) – NS
Hussein Abulhassan (Egypt) – NS
Manoj Khanna (India) – NS
Paul Audi (Lebanon) – NS
Moazzam Tarar (Pakistan) – NS
Toh Lee Peter Wong (Malaysia) – NS
Theddeus O. H. Prasetyono (Indonesia) – NS
Mohamed Farouk Abdelaziz (Kuwait) – NS

Elections Pending

Australia – ANS
Bolivia – NS
Ecuador – NS
Germany – ANS
Russia – NS
Turkey – NS

NATIONAL SECRETARY GALLERY



NATIONAL SECRETARIES

TWO ASSISTANT NATIONAL SECRETARIES FOR ITALY



ADRIANA POZZI, MD - ITALY
ISAPS National Secretary for Italy

In February, we elected two Assistant National Secretaries due to the growing number of Italian members, among them many young surgeons who were included in the fast track application we did last summer. We also wanted to appoint an assistant to represent the north of Italy and another for the south of the country, belonging respectively to SICPRE and AICPE, the two Italian National Societies.

There was a feeling of electrifying enthusiasm during the days of the elections.

We had four members competing for this position and the successful candidates were Dr. Andrea Margara and Dr. Francesca De Angelis.



Andrea Margara got his Board Certificate in Turin, where he completed his residency in 2006, and after that he started working as a consultant in many clinics. He is an active member of our Society, and also of the Italian Society of Reconstructive and Aesthetic Plastic Surgery (SICPRE). Currently he works as an independent plastic surgeon in northern Italy. He has a special interest in post bariatric surgery and body contouring, breast surgery and all cosmetic procedures including aesthetic medicine.



Francesca De Angelis is a Board Certified Plastic Surgeon who qualified in Naples in 2005 with a PhD in regenerative surgery. She is an active member of our Society and of the Italian Society of Aesthetic Plastic Surgery (AICPE) and (SICPRE). She is also a member of the American Society for Laser Medicine and Surgery (ASLMS). She has been working in the field of Laser surgery and aesthetic medicine since 2001, involved in many clinical and experimental trials concerning new laser technology research and new rejuvenating approaches.

During the annual AICPE Congress, a party was organized to welcome our two newly elected Assistant National Secretaries who were very warmly greeted by our ISAPS members.

Altogether, with our Vice President Gianluca Campiglio, the Italian ISAPS team has expanded.

ISAPS BOARD OF DIRECTORS MEETING


NEW ORLEANS, LOUISIANA, USA –
MAY 17, 2019



Front Row: Drs. Ivar van Heijningen - Belgium (Secretary), Arturo Ramirez-Montanana - Mexico (3rd Vice President), Nazim Cerkes - Turkey (President-Elect), Dirk Richter - Germany (President), Lina Triana - Colombia (1st Vice President), Kai Schlaudraff - Switzerland (Treasurer), Renato Saltz - US (Past President); Back Row: Peter Scott - South Africa (Historian), Tim Papadopoulos - Australia (Parliamentarian), Ozan Sozer - US (EC Vice Chair), Vakis Kotoes - Greece (EC Chair), Fabian Cortinas - Argentina (Trustee), Michel Rouif - France (National Secretaries Chair), Catherine Foss - US (Executive Director). Not pictured, Dr. Gianluca Campiglio - Italy (2nd Vice President)

ISAPS JOURNAL

MESSAGE FROM THE EDITOR-IN-CHIEF



BAHMAN GUYURON, MD - UNITED STATES

During the last Editorial Board meeting, we formed a committee to be chaired by Dr. Lisa Gfrerer, the Resident Editorial Board member, with participation by Drs. Steve Cohen and Ash Ghavami, Editorial Board members, to launch our social media activities.

I am pleased to announce that *Aesthetic Plastic Surgery* social media is now live on **Facebook (Aesthetic Plastic Surgery Journal)**, **Instagram (aps_journal)** and **Twitter (@aps_journal)**.

Please make sure to check in for your update on international aesthetic plastic surgery research, article highlights and author introductions. APS and ISAPS social media are now linked and our selected authors' work is featured on all media. The goal is to disseminate the content of the interesting articles to colleagues and the public intentionally. The committee members select the articles to be featured on social media after the articles have been accepted and lined up for publication in each issue of the journal.

I wish to express my deepest gratitude to Lisa, Steve and Ash for their time and effort. I believe that this activity is timely and will provide international exposure to articles that are deemed to be of the highest level of interest to colleagues and the public.

I am also happy to report that our submission rate has increased substantially over the first quarter of this year. I will share statistics with you in my next message.



We invite you to submit a paper to our journal.

For information go to:

<https://www.isaps.org/medical-professionals/isaps-journal/>

MARKETING

A COMPREHENSIVE GUIDE TO REAL-TIME MARKETING: THE POWER OF NOW



SAMUEL PEEK, CEO
Incredible Marketing

The year is 2005. Millions of Americans are tuning in to ABC's premiere of a new primetime drama featuring the lives of doctors that would soon attract a global audience in over 200 countries. Over the course of 14 years, *Grey's Anatomy* has not only kept its original fan base begging to see their favorite surgeon week after week, but it has also gained a new following through DVR and streaming services. Those who didn't follow the show in real-time now have the ability to binge watch it whenever they want -- if they're a millennial, maybe even binge watch it all at once!

But why? Why are people tuning in year after year? People want to know what goes on in the lives of lawyers, doctors, investigators and other exciting professionals who deal with life and death; quite frankly, it makes perfect sense. Healthcare professionals lead exclusive and interesting lives when they hang up that white coat at the end of their shift -- or so we have all been led to believe. *Grey's Anatomy* highlights the fact that even the most renowned doctors have a deeply personal story that exists simultaneously in a crazy, unpredictable medical world.

Imagine for a moment if prospective patients could see your life through a magical telescope. No, really. Close your eyes for a second and imagine it. Now, imagine that this magic telescope would allow you to curate all aspects of your life, so your patients only see the highlights and positive things about you and your practice. You have the power to share -- or not to share -- what you want -- at your own discretion. Before they choose to book a consultation, they gaze into this

magical telescope to learn more about who you are. Trust is a part of this decision-making process -- so, what would you share and how much?

It's 2019. Sadly, these magical telescopes don't exist -- but we do have social media, which actually gives us very similar powers. We're a heavily connected society who can now take a glimpse into the lives of people from all over the world the way we see our galaxy through a telescope. Venus burns brightly in the sky, but it's not the only radiating planet -- it is always in competition with the moon, Jupiter and Mars. Like Venus in the solar system, you want to separate your practice from a crowded solar system. Social media can help you achieve this and more. Through social media marketing, you are turning your telescope into a microscope -- allowing your prospective patients to take a closer look at your practice and building increased credibility and trust. The best part? Your time is the only initial investment.

As a plastic surgeon, how do you reach new patients and increase your brand visibility? Marketing 101: You go where they go. If you're not part of this social galaxy that nearly 3 billion people are a part of, then there is no time like the present to start. It's not too late to learn how to use some -- or all -- of these social media platforms to create a refined, real-time patient experience.

Continued on page 30

So, what is Real-time Marketing and how can it revolutionize my ROI?

People are fascinated by *reality* – people in real time with real emotions. This is why reality TV has taken over around the world and captured such large audiences. Real-time marketing (RTM) creates a seamless and instant connection with your audience through events happening in *real time*. This is achieved through the “live” feature on Facebook, Instagram and other RTM social services. However, you don’t have to wait for “breaking news” to capitalize on RTM; you can also *plan* RTM. If you know your message and target demographic, RTM can be a highly effective method to engage with prospective patients. Even though live streaming involves improvisation, there is preparation that precedes this spontaneity, just as in traditional marketing.

Time is money. Even a small investment in time can get more eyes on who you are and what you do. Aim to create content that is *timely, relatable, organic and shareable*. As the expert, you can add value by creating RTM content that is patient focused. Here are just a few great topics to give you some ideas:

“Let’s Talk: FAQ’s”

“Plastic Surgery Myths Debunked”

“My Take on Saline vs. Gummy Bear Implants”

“This is How You Identify Which Procedure is Right for You”

“How to Pick the Perfect Surgeon Based on Your Aesthetic Goals”

**NOTE - To avoid violating HIPAA in the US and other international privacy laws, make sure you always get written consent from your patients before publishing any content containing their likeness on social media.*

Here is a beginner’s guide to getting your RTM campaign started:

Identify the message: Is there breaking news in healthcare that your patients should be educated about? Is your message educational, inspirational, humorous, patient-focused or behind-the-scenes content of a procedure? For example, showing a patient’s journey before and after a tummy tuck would be an exclusive look into patient care and progress, which is highly relevant to prospective patients interested in that procedure.

Develop a strategy: You can’t market effectively without a plan. Based on the *timeliness, relevance, relatability, shareability and authenticity* of the message, prepare your campaign accordingly. If it is not a timely message, give yourself time to promote the message before you go live. Develop a schedule in your social media strategy for monthly, or weekly, live streams. For example, start with a format based on your availability. Every X number of weeks, schedule a live stream on Instagram and Facebook. Save the live streams for playback for viewers who weren’t able to tune in to the broadcast. Keep in mind that authentic and shareable content resonates deeply with your ideal patient. Posting patient testimonials, FAQ’s, procedure information and post-procedure tips would all be authentic, shareable content.

Identify the platform: Which platform will your message be on? One, two or all? Always choose what is right for you first – this will resonate with your demographic.

How to pre-market your live stream to attract new patients: Think of RTM as a live event you are hosting. You wouldn’t throw an event without advertising it beforehand! Treat your live streams the same way. Tease your followers on Instagram and Facebook with sneak peeks of topics you will be covering. For example, you could compose a post like this:

“Have you ever wanted to know about the different techniques used in facelifts? Join me live next Thursday – I’ll be answering all your questions and giving you all the need-to-knows before you book a consultation with your surgeon! There may or may not be a giveaway at the end...”

You can do this through Instagram Stories and Facebook feed posts. Get creative with it, and have fun! You can offer your followers incentives (maybe special deals or gift cards) for tuning in and asking questions. For extra visibility and reach, promote your posts through social ads. Instagram and Facebook have an array of updates for you to engage with your target demographics.

Facebook: Facebook Live is completely free, and all you need is a reliable phone with high camera quality. Give Facebook access to your camera and make sure your privacy settings are public. Select “Live” on the bottom of the screen when



MARKETING PLAN

you're in the Facebook App. Write a detailed description of what the Live entails and tag your location and friends in your stream. Click "Finish" when done and save to your camera roll to repurpose on other platforms.

YouTube: Go to your channel and enable Live Streaming. Accept the terms and conditions and you'll be good to go. Save the video to your channel once finished and share across your other social platforms.

Instagram: Open your camera on Instagram and select "Live" at the bottom of the screen. When finished, click "save to Story for 24 hours" and also save to your camera roll. Create a highlight on your profile for your live streams to live in for playback. Tag the location and guests featured, if any.

Execute: Now that you have your message and strategy, it's time to execute. If you don't have a videographer, invest in a tripod. Ensure the location of the live stream is consistent with your branding. Once you're live, you won't need to fiddle with the camera until it's time to stop. Make sure to answer your audience's questions and interact with them during your broadcast.

Lessons and feedback: Reflect. What was your patient feedback like? Track the analytics of your broadcast and measure comments and likes so you can compare your statistics to future sessions and monitor your growth. To create a real-time opportunity within your reflection, ask your followers what they thought of the live stream and what they want to see more of for the next broadcast!

Why is RTM beneficial for my practice?

Patients are no longer looking *solely* at your website. Believe it or not, your 500-word summary on breast augmentation is just not enough anymore. Patients want to know more, see more and learn more -- RTM delivers that on a silver platter

as *insurance*. Additionally, you have the option to create a budget for targeted social ads (paid social promotions) to boost your content to the top of your ideal patients' social feeds.

Much like *Grey's Anatomy*, RTM draws people in. We have all witnessed the successes of the brightest social media "stars" -- like Dr. Miami, Dr. Nazarian and, of course, Dr. Pimple Popper! People crave sensational content that heightens their emotions, and they have a deep curiosity -- especially about healthcare -- which real-time marketing satisfies.

RTM isn't for everyone, and that's okay.

RTM isn't for everyone -- not every surgeon or doctor can pull it off. It requires vulnerability, trial and error and risk. RTM is a marketing tactic that takes on many shapes and places the patient's experience first. Discover your *why* and identify whether it aligns with your patient's surgical journey: can they relate to you? Not every surgeon can connect with their patients personally, frequently and in real-time, and that's okay. Figure out what digital marketing technique works best for your practice -- but remember, some of the best RTM is not completely polished, "made for camera" moments -- it's real . . . just like you.


You won't get thousands of followers and viewers overnight from a single live stream, but you can build a strong online presence if you adopt a social media strategy that fits your brand and stick to it. The key is consistency, timeliness and relevance. Make sure your message directly connects to your ideal patient and always ties back to your brand. You might not gain red-carpet privileges like the surgeons on *Grey's Anatomy*, but you'll gain credibility and the loyalty of *real* patients, which is far more meaningful. Before long, through RTM and the power of now, you will begin to shine much brighter than the other stars in the night sky.

CASE STUDY

THE CUT AND SLIDE OTOPLASTY MAKES AN OLD DREAM COME TRUE



**ITHAMAR N. STOCCHERO, MD -
BRAZIL**



**GUSTAVO F. STOCCHERO, MD -
BRAZIL**



**GUILHERME F. STOCCHERO, MD -
BRAZIL**



**ALEXANDRE S. F. FONSECA, MD -
BRAZIL**

One day in my office, I received a thoracic surgeon, very well-known in my country and abroad. He was 68 years old and, retiring from his practice in surgery, decided to dedicate his time to music. He is a graduate classic guitar player and told me that there was something that



Figure 1 - Patient, 6 years old.

had annoyed him, in some way, all his life: his prominent ears. "There was always that six-year-old boy inside me." (Figure 1). When he was younger, he used to have long hair and did not experience many inconveniences; but nowadays, with these new stage perspectives, he was interested to solve the problem.

I developed this technique, the cut and slide conchal treatment, twenty years ago to reduce ear prominence, to be more easily performed, and to offer less postoperative pain.

It is carried out under local anesthesia, and employs an elliptical resection of skin, fat and muscle behind the ear. After the exposure of conchal cartilage, a crescent-shaped incision is done followed by undermining of the anterior border of the cartilage (Figure 2), which must

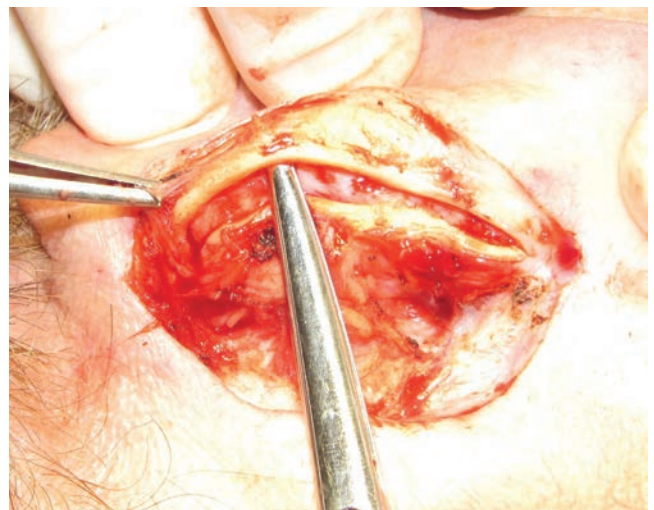


Figure 2 - Crescent-shaped incision.

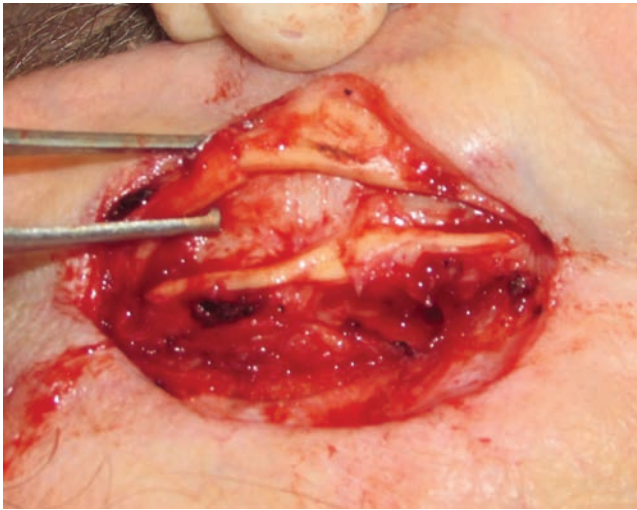
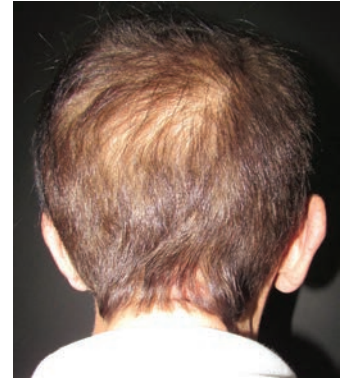
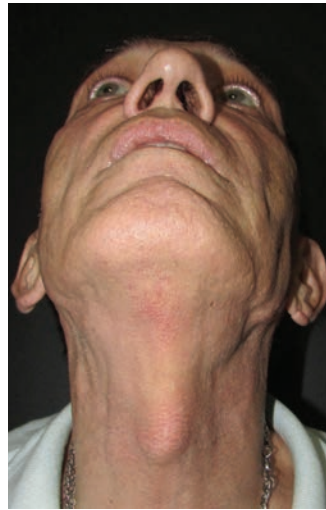Figure 3 - Preparing to slide the anterior flap over the posterior.



Figures 5 & 6 - Patient, 68 years old - preop.

be large enough to allow for its sliding over the posterior cartilage flap, up until the postauricular sulcus (Figure 3). Suture of cartilage and skin (Figure 4).

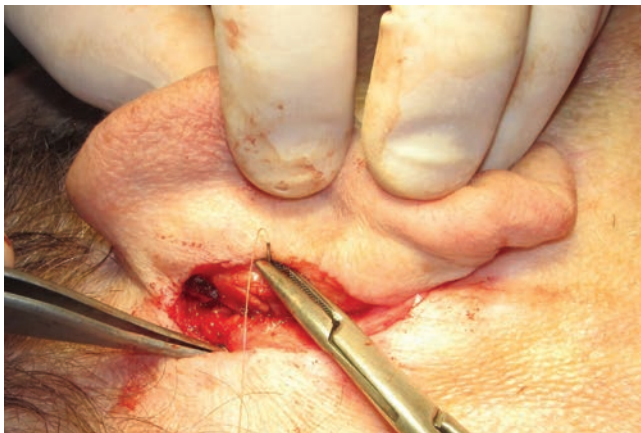
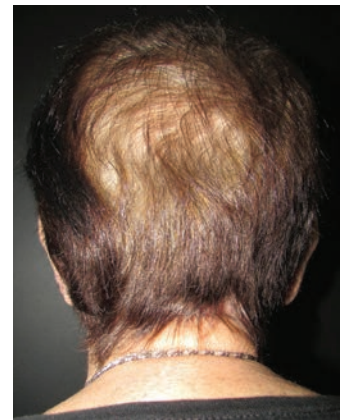
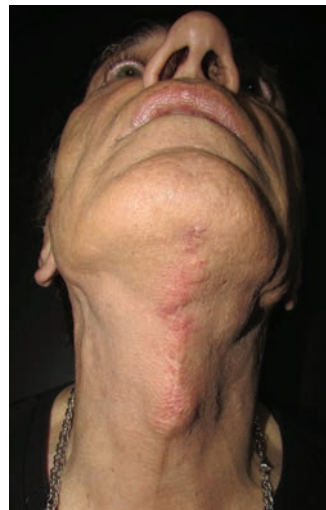
Figure 4 - Suture of the cartilage.

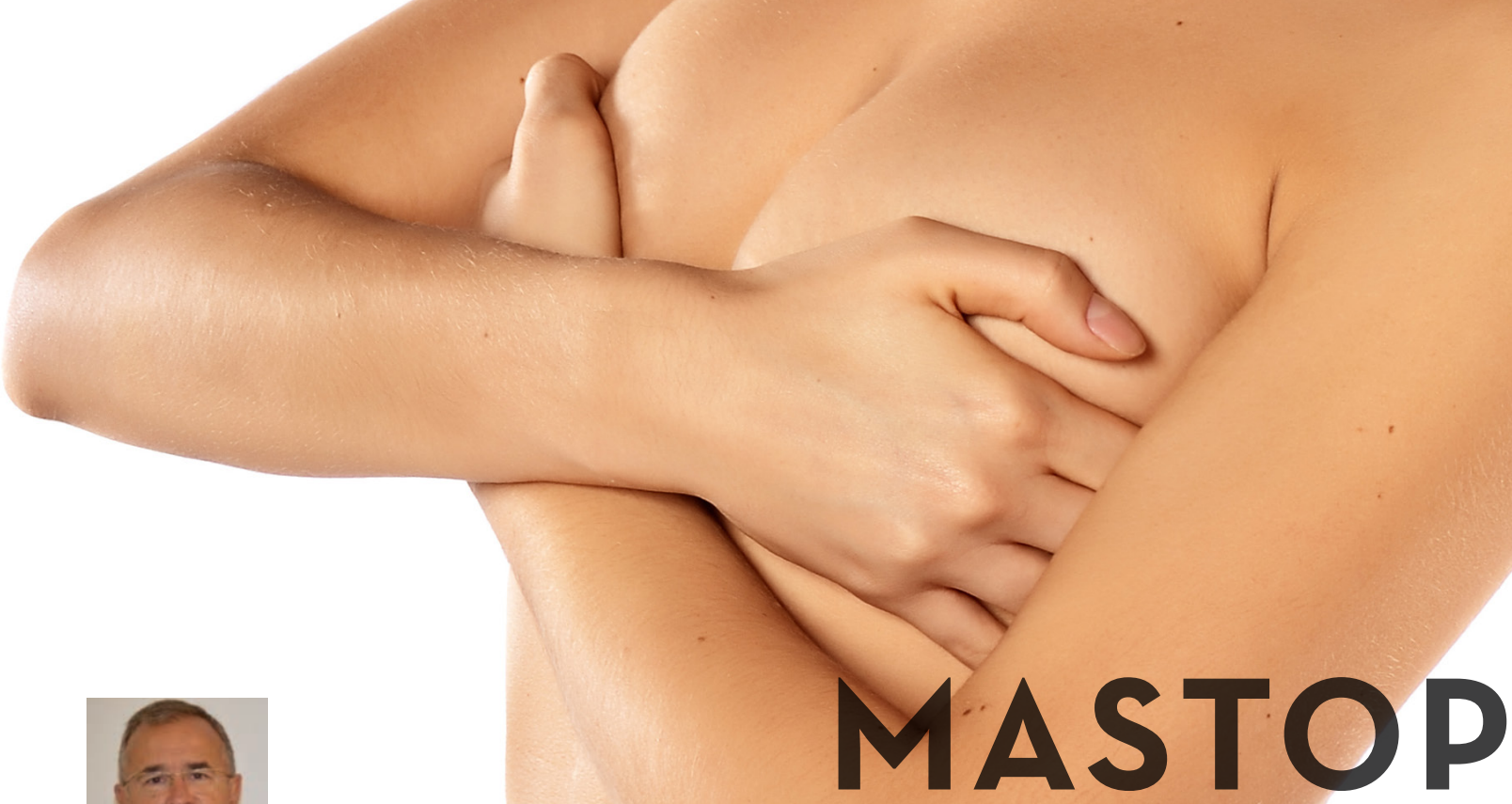

Figures 7 & 8 - 45 days postop.

Sometimes people suffer from a lifelong unhappiness with small things that are so quick and easy to solve. Plastic surgery gives us the opportunity to offer a happy smile to so many people. (Figures 5 and 7; Figures 6 and 8).

Reference:

Stocchero IN. The Cut and Slide Conchal Treatment, *Plast. Reconstr. Surg.* 113(7):2236-2237, 2004.



MASTOP



GUILLERMO SIEMIENCZUK, MD - ARGENTINA

GLOBAL PERSPECTIVES

CURRENTS TRENDS IN MASTOPEXY

Today's concern about the problem of Breast Implant Associated Anaplastic Large Cell Lymphoma (BIA-ALCL), which undoubtedly has come to our specialty area to stay for a long time, compels us to reconsider mastopexy's key concepts.

This explains why I have stopped using textured implants of any brand for the last six months, unless a patient explicitly requires me to do so and as long as such request is stated on the informed signed consent form. Instead, I use smooth implants, then choosing the profile from moderate, high to extra high adapting them to each case, as there are not smooth anatomical implants available at the moment in the market.

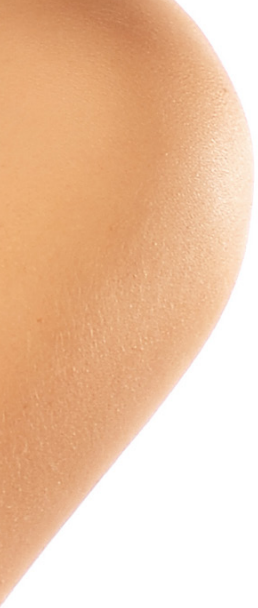The measure at the base of each patient's hemithorax defines the implant's base diameter and the profile or

projection depends on the patient's excess tissue and sagging skin and on her preference over the type of height of the upper pole, which will be more or less evident.

The implants I use are generally small – between 270 and 390cc – as the outcome to achieve in terms of the breast's volume is the sum of the volume of the breast itself, plus the implant's volume.

The high rate of ptosis recurrence with smooth implants is associated with the weight or volume of the implant we use. The heavier the implant, the earlier the recurrence, added to the great mobility of the sub-muscular smooth implants, since these do not have the Velcro effect of the textured or polyurethane options.

I always place smooth implants on the partial sub-pectoral plane, or John Tebbetts dual plane (sub-glandular and



EXY

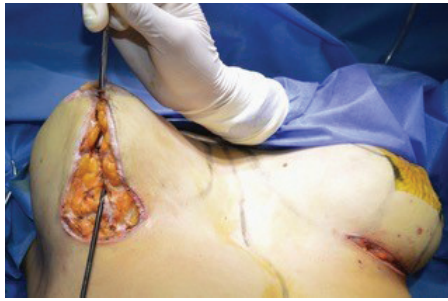

Figure 1 - Both implants placed and closed, still with nipple shields on left side.

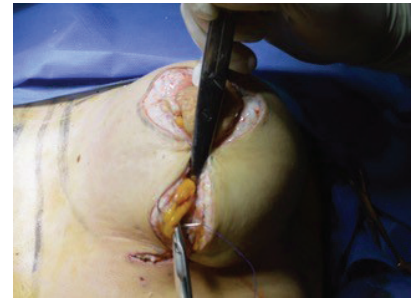


Figure 2 - Remove the excess tissue.

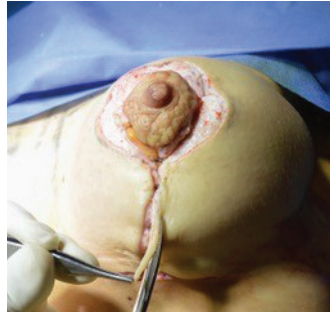

Figure 3 - Adjusting skin resection.

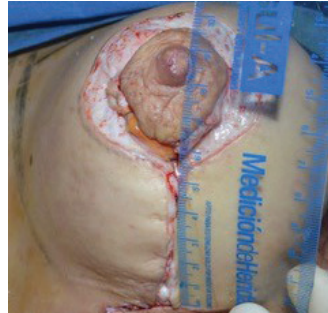
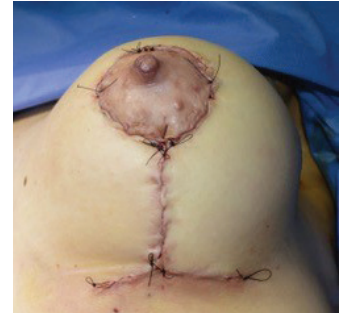

Figure 4/5 - Adapting "in situ" the previous marking.



submuscular), with Omar Ventura's modification that is sub-fascial and submuscular.

I choose this pocket location regardless of the thickness of the patient's tissue that will remain over the implant. It is important that the complete transverse pectoral section be at the level of the fourth intercostal space so that the implant can descend with the gland with the passing of time, and so that it will not be trapped in the upper pole, thus producing the double bubble deformity.

At the time of the surgery, I prefer to make the incision first in the inframammary fold, and perform the implant surgery complying with the 14 steps recommended by W. P. Adams in order to diminish the possible implant contamination, except for the use of Betadine because we use only saline solution. With the implant in position, we close the fascia with PDS 2-0 and fix the inframammary fold to keep it in position. Then we perform the pexy incisions to remove the excess tissue, adjusting skin resection to the new volume obtained with the implants, adapting "in situ" the previous marking. In this way, we prevent excessive tension in the vertical and peri-areolar sutures, and in the very unlikely case that they dehiscence, it will not leave the implant exposed,

requiring explantation. We also use PDS 2/0 sutures and 3/0 Vicryl, then close the skin with nylon 3/0 running subcuticular suture.

Regarding the areolar sutures, they need to be strong enough to maintain the tension imposed by the implants. That is why we make a round block with 3/0 nylon very deep, with a buried knot so that it passes unnoticed and it cannot be exposed. Finally, we put micropore on all the sutures. Using drains is very infrequent.

These new concepts, which consist of using smooth implants in a dual plane pocket location and separating the surgery into two stages, as if they were two different surgeries, with the aim of avoiding the implants' contamination, mandates that all our mastopexy procedures have T inverted scars, where the horizontal component measures at least 4 cm.

We already know that so many scars are far from ideal, but we prefer to deal with the subsequent treatment to improve their quality, rather than having to face a possible seroma, or the implant's exposure and capsule contracture.

We value Charles Darwin's quote: "It is not the strongest of the species that survives, nor the most intelligent that survives. It is the one that is most adaptable to change."

AUGMENTATION MASTOPEXY

5TH GENERATION TECHNIQUE, NEW IMPROVEMENTS



RAMON J. NAVARRO CEBALLOS, MD - MEXICO

Introduction

Mastopexy is among the most requested surgeries by women from 18 to 50 years old, with an active sex life. There is more than one classification of breast ptosis; however, the most effective diagnostic measurement is the descent of the nipples beyond the imaginary transverse line that joins the midpoint of each arm. The correction of ptosis is not only achieved with the placement of breast prostheses. For correction, another complementary procedure is required. The most frequent error is to try to correct the ptosis with the placement of larger than adequate implants, resulting in an exacerbation of the defect and apparent obesity of the patient, as well as recurrent ptosis.

The objectives of the surgery are: 1) greater turgor to the breasts, 2) decrease in the transverse diameter of both breasts, 3) producing an antero-superior projection of the breast instead of volume, 4) decreased size and weight, and above all, 5) placement of the nipple in its ideal position and without recurrence of ptosis. It is important that when the placement of an implant is required, it should be as small as possible, but preferably teardrop medium projection. The mastopexy has had continuous improvements throughout its existence.

Study Size

Twenty female patients from 18 to 65 years old with breast ptosis.

Method

With patients in the standing position, traditional marking was done. With a hemi-circle upper areolar exactly as usual typical marks are drawn (the projected upper border of the areola should stay in a crossing vertical hemi-clavicular line 22cm from an oblique projection line from the middle of the upper sternal border), and the implants were placed in a subfascial way to avoid recurrence of ptosis. Post-operative evaluation was carried out between one month and one year.

Technique

Klein fluid infiltrated both breasts. The de-epithelization of both half-moons was performed, using a standard basal tourniquet. Subsequently, a cut was made at 0.5cm from the lower edge of the ellipse. The dermal flap was raised up to 2cm before the upper areolar border, moving it towards the nipple. Afterwards, the internal superior quadrant of the breast was removed, with the help of an electric scalpel, and in depth up to the muscular fascia. Tension for closure was avoided by suturing in three layers.

After more than eleven years, there has been no relapse. The simplicity of the technique allows us to combine others, such as liposuction, abdominal, axillary, and dermo lipectomy. In 90% of the cases, the surgery was ambulatory. Only in combined surgery, the patient spent 24 hours at the hospital.

Results

Ptosis between 5 and 12 cm was corrected, without recurrence or postoperative pseudo-ptosis. Physical exercise was possible 15 days after surgery with the support of an elastic bra. Healing was highly satisfactory. The only complications presented were partial dehiscence in two patients, burning sensation and tightness, and elongation of the areola in patients whose ptosis exceeded 12cm with large areolae. The ease of execution and safety allows surgery to be ambulatory.

Complications

During the normal learning curve in one patient, we had partial dehiscence on one side, and in another partial dehiscence that required correction with local anesthesia. The discrete elongation of the areola is one of the minor complications that merits subsequent secondary correction. However, in small areolae, this does not happen, or is minimal.

Conclusions

This fifth-generation technique is proposed to avoid peri-areolar scar, inframammary, vertical and inverted "T", in addition to eliminating the internal superior quadrant significantly reducing the possibility of developing further cases of breast cancer. It also avoids the sensitive sexuality problem, staying away from lateral sensitive nerves.

Comment

The histopathological results were of fibrocystic mastopathy in 80% of the cases. Multiple intraductal papillomatosis was only reported in a single case of exchange of implants and it was treated with three doses of human papilloma virus vaccine and followed by a gynecologist. In two other cases, we obtained ductal ectasia. We insisted on the type of implant, preferably microtextured, high profile, maximum cohesiveness.

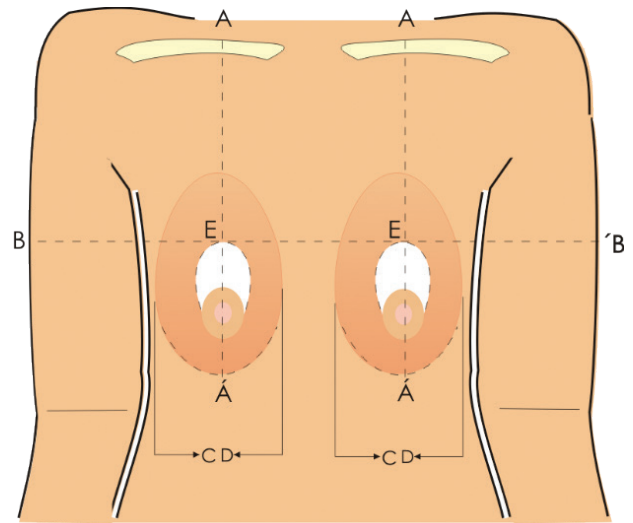


Figure 1 - a. Clavicular midline; b. Transverse half of both arms; c-d. Width of the breast; e. Crossroads of lines (future position of the halo)

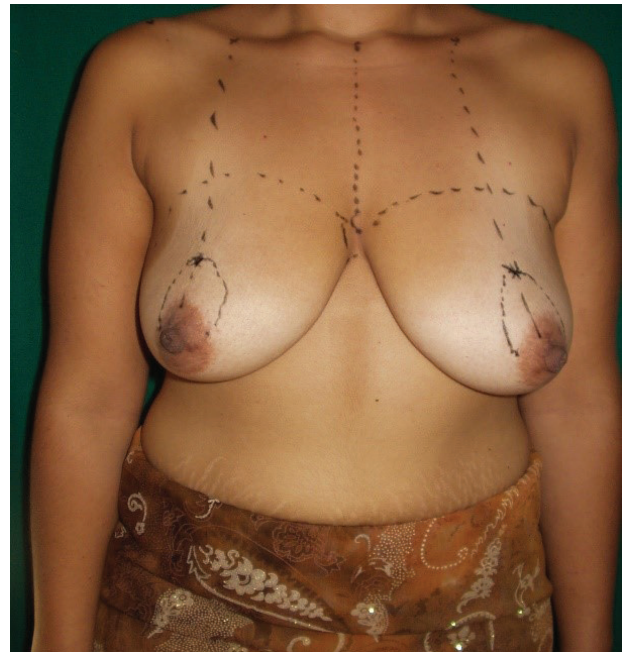

Figure 2 - Patient with preoperative marking, standing position.

MASTOPEXY

CONIZATION AND MASTOPEXY OF BREASTS WITH SILICONE IMPLANTS BY MEANS OF TWO INCISIONS OF A FEW MILLIMETERS AND ELASTIC THREADS MOUNTED ON TWO-TIPPED NEEDLE



SERGIO CAPURRO, MD - ITALY

Introduction

Implanting breast prostheses, especially if they are large, changes the shape of the breasts, which lose their natural conical shape and become rounded. Subsequently, gravitational ptosis detaches the prostheses from the chest wall. Under the weight of the prostheses, the tissues stretch and the diameter of the areolae increases. These breasts look like spherical formations connected to the chest wall by hollowed-out skin (**Fig. 1**). Today, the appearance of these breasts can easily be improved and made more natural by means of an ambulatory Elastic Plastic Surgery procedure. This procedure restores the conical shape of the breasts, repositions the implants in contact with the chest wall, reduces the areolae and realizes the mastopexy. (**Fig. 2**)

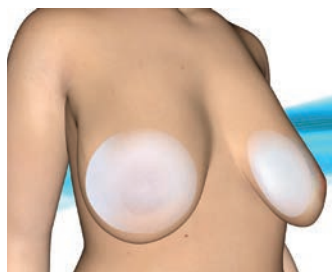

Figure 1 - Round and drooping breasts with implants.

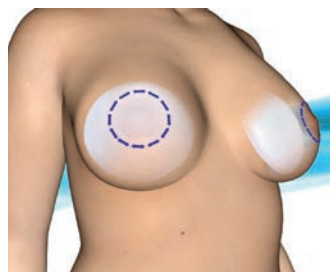


Figure 2 - Conization and mastopexy by EP4 Elasticum thread.

Procedure

Local anesthesia is performed with 2% mepivacaine with epinephrine in the incisions and in the tunnel. A diluted anesthesia is carried out along the pathway of the elastic threads. The anesthetic consists of 15 ml of 2% mepivacaine and 1 mg of epinephrine, which is added to 250 ml of Ringer solution or physiological solution.

The procedure is carried out through one periareolar incision of 8 mm per conization and one incision of 2 mm on the anterior axillary line for mastopexy.

An elastic thread with Jano needle (EP4 Elasticum, Korpo) is implanted through a tunnel at about 6 cm from the nipple, at a constant depth, ranging from 1/2 cm to 1 cm, according to the thickness of the patient's tissues (**Fig.3**). A spreader is inserted into the tunnel. The two-tipped Jano needle enters the tunnel and partially emerges on the outer circle. The operator extracts the two-tipped needle until 0.5 cm of the posterior tip remains in the tissues, as

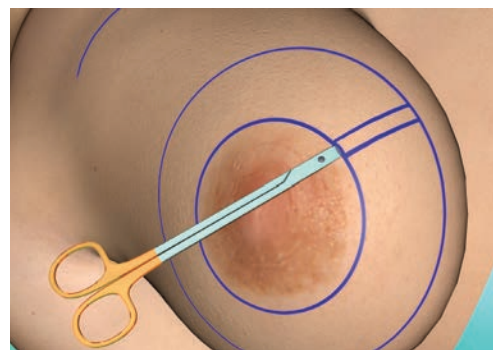


Figure 3 - A tunnel is made at the depth of implantation of the elastic thread (from 1/2 cm to 1 cm).

indicated by the depth-marks on the shaft of the needle. The needle is then rotated and follows its pathway along the preoperative design. By means of slight up-and-down movements, the operator checks that there are no skin indentation and that the needle is following a uniform pathway through the subcutaneous tissue. During these maneuvers, the operator must take care to ensure that the Jano needle does not come out of the skin, because any attempt to reinsert it through the same hole will cause a skin indentation. If it does come out, the operator will have to extract the thread and repeat the implantation from the beginning. Once the needle has been passed circumferentially, the Jano needle is rotated and, with the aid of the spreader, emerges through the tunnel (Fig.4 -Fig.5). The elastic threads are placed under tension and knotted under the guidance of the spreader.

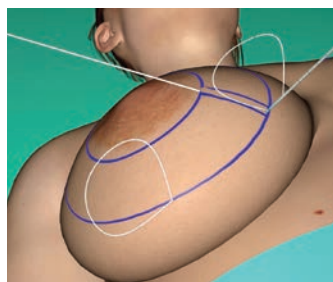


Figure 4 - The two-tipped Jano needle enters the tunnel and partially emerges on the outer circle.

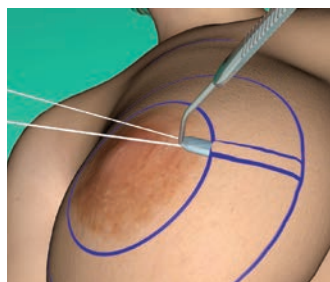


Figure 5 - After rotating 180 ° several times to the predetermined depth, the needle leaves the tunnel. Now the breast is conical.

A second elastic suture, which is implanted in a circle around the areola cones the central mound of the breast and prevents the areola from dilating and the sub-areolar tissues from atrophying (Fig.6). Conization improves the appearance of breasts with silicone implants and counteracts drooping.

In the case of drooping breasts, lifting is carried out in addition to conization. The operator raises the breast with one hand and marks the point

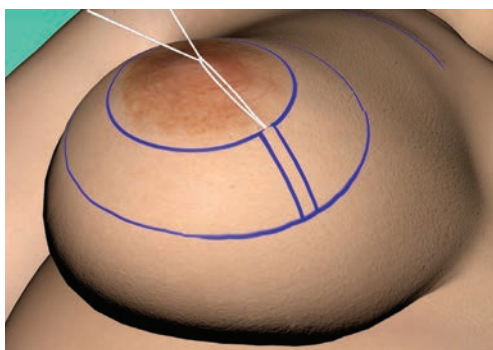


Figure 6 - The periareolar elastic thread is implanted, the apex of the breast is now conical.

where the skin of the chest begins. The patient is placed in a sitting position and the operator uses a dermatographic pen to mark the most prominent point of the lower quadrant. From this point, he then draws an ellipse, which connects with the preoperatively drawn mark that indicates the point where the skin of the breast meets that of the chest.

The elastic thread that will be used for mastopexy will be anchored to the subcutaneous tissue at this point (Fig.7).

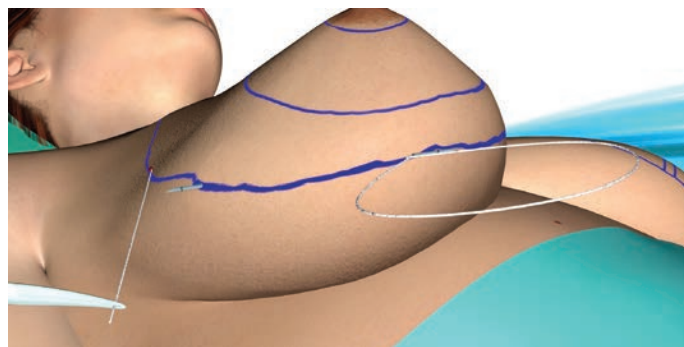


Figure 7 - The breasts have been made conical. The elastic thread attached to the thoracic subcutaneous tissue creates the mastopexy.

Discussion

We have designed the Elasticum thread and the Jano needle and cannula to avoid traditional lifting dissection of the cheeks and neck and to lift the breasts and buttocks. Owing to its elastic properties, this new surgical thread does not cut into the tissues. On account of their anatomical structure, the subcutaneous tissues of the breast and chest constitute a suitable suspensive structure.

In a few weeks, the elastic thread is transformed into a “natural ligament”, which consolidates the suspension. Lifting the breasts by means of the elastic thread yields a permanent result.

Breasts that have silicone implants are given a conical shape and are lifted by elastic mastopexy. They have a natural, pleasing appearance, and no longer look artificial (Fig.8).

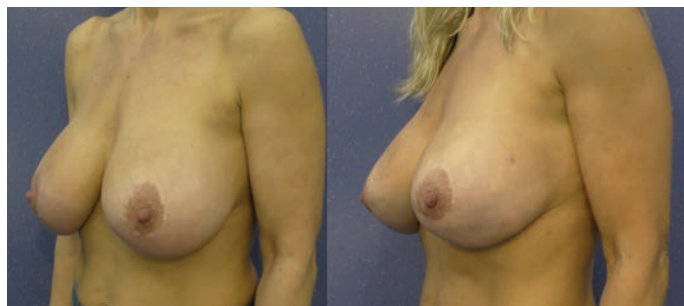

Figure 8 - The procedure restores the conical shape of the breasts with silicone implants and realizes a natural mastopexy without visible incisions.

Conclusion

A simple, minimally invasive surgery allows you to improve small and large breasts with silicone implants naturally. Elastic Plastic Surgery is a section of the www.crp.org Open access Medical Video Journal.

The author is a shareholder in the Korpo Society that produces the elastic suture.

MASTOPEXY

WISE PATTERN AUGMENTATION MASTOPEXY WITH A SHORT HORIZONTAL SCAR



BABIS RAMMOS, MD, FACS - UNITED STATES



BILL G. KORTESIS, MD, FACS - UNITED STATES



GAURAV BHARTI, MD, FACS - UNITED STATES

Summary

The Wise pattern augmentation mastopexy technique is used when there is Grade II or III ptosis, vertical and horizontal skin excess, the lower breast area is relatively full, and the nipple-areola complex requires a long transposition. Patients that benefit from this technique, have flattening of the superior pole, and most of the breast parenchyma is below the inframammary fold. In these cases, simply tightening the skin over the supporting breast is not adequate, and a breast implant is necessary. Goals and expectations of the patient are discussed in detail during consultation, and a thorough personal and family history is performed. Physical examination

focuses on current breast size, degree of ptosis and any breast asymmetries. The patient is marked in the upright standing position and brought to the operating room.

Technique

Wise pattern augmentation mastopexy with a smooth round silicone implant, partial subpectoral placement and dual plane creation.

The patient is brought to the operating room and placed in the supine position on the operating table with the arms extended up to 90 degrees. The patient is sat up to evaluate the preoperative status (Figure 1). Local anesthesia containing

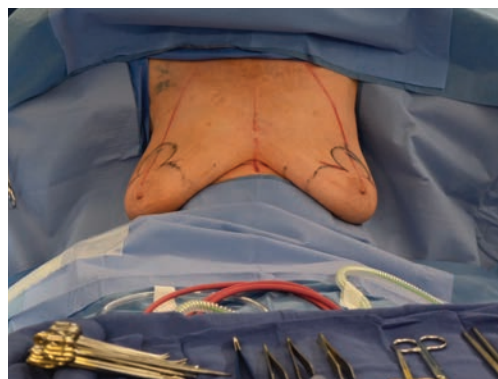

Figure 1 - Intraoperative frontal view of the patient positioned on the operating table. The patient is placed in an upright seated position for initial appreciation.

a mix of lidocaine and Marcaine with epinephrine is injected into the marked pattern, and as a breast block.

A vertical incision is made sharply within the

mastopexy resection pattern, dividing the breast tissue, and carried down with cautery to the pectoralis fascia. The pectoralis muscle is grasped and divided till the areolar space under the muscle is identified. A lighted retractor is then placed below the pectoralis major muscle and strong upward traction is placed so as to separate the pectoralis major from the pectoralis minor muscle. Pocket dissection

is performed with the monopolar electrocautery and there is no use of blunt dissection. Submuscular dissection proceeds from medial to lateral in a clockwise fashion for the left breast and in an anticlockwise fashion for the right breast, until the pocket is of appropriate size. Care is taken to avoid any contact with the ribs so as to decrease postoperative pain.

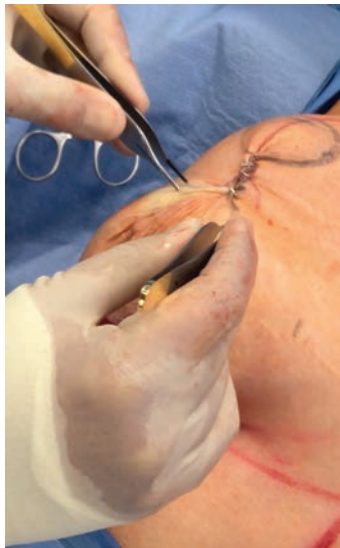

Figure 2 - After placement of the tester gel implants, the breasts are temporarily stapled closed.

(Figure 2). A 7 cm inframammary fold-areola distance is used, and an appropriate elliptical mastopexy pattern is designed (Figure 3). The patient is placed in the upright seated position and symmetry is confirmed. If there are areas for additional dissection, these are marked.

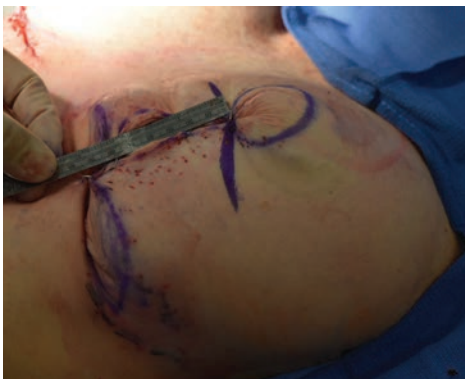

Figure 3 - The no touch technique is used. The implant is transferred to the Keller funnel without being touched.

The implant is transferred to the Keller funnel avoiding any contact with the operating table or the surgeon's gloves (Figure 4). A Deaver retractor is used by the assistant to facilitate placement of the implant. The pockets are closed with 3-0 Vicryl. The skin is then tailor tacked, and the patient is placed in the upright position again to verify the mastopexy marks. The nipples are traced with a 42 mm cookie cutter. The areola is left in situ. The marks are incised sharply, and the intervening skin de-epithelialized. An incision is made

The medial origin of the pectoralis major muscle is disinserted, so as to achieve adequate expansion of the lower pole. Meticulous hemostasis is achieved. Tester gel implants are placed and the breasts are temporarily stapled closed

The tester implants are removed, and the pockets are irrigated with triple antibiotic solution. The formal implants are then placed in a sterile manner using the no-touch technique. The implant is

with the cautery around the periphery of the vertical limbs. The inferior portion of the areola pedicle is released with cautery, thus creating a superior pedicle, to allow for superior motion and inset without tension. A small wedge of tissue is removed from the vertical limb to improve the contour. The elliptical mastopexy pattern is removed full-thickness with great care not to enter the implant pocket, and the resected amounts are recorded. With the shape and size confirmed with the patient sitting up, vertical pillar breast sutures are placed, on average a total of 3 interrupted sutures (2-0 Vicryl). The skin is closed in layers with interrupted 3-0 Monocryl for the deep dermis and a running subcuticular 3-0 Monocryl more superficially. The patient is placed again in an upright seated position for final appreciation. (Figure 5).

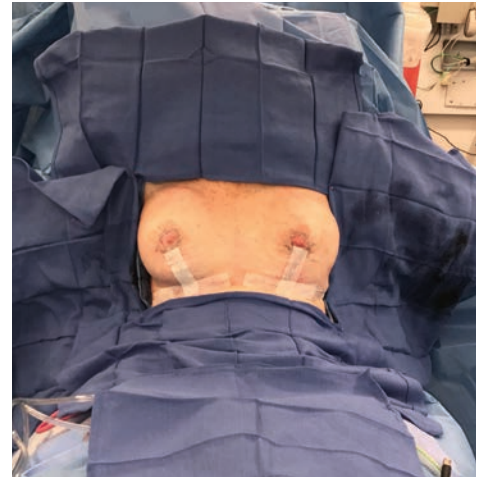

Figure 5 - Intraoperative frontal view of the patient positioned on the operating table. The patient is placed in an upright seated position for final appreciation. A bilateral Wise pattern augmentation mastopexy was performed.

Postoperative Care

Patients are discharged at the same day of surgery after they recover in the postoperative anesthesia care unit (PACU). Postoperative medications include oral analgesics and a 7-day course of oral antibiotics. A soft bra is placed.

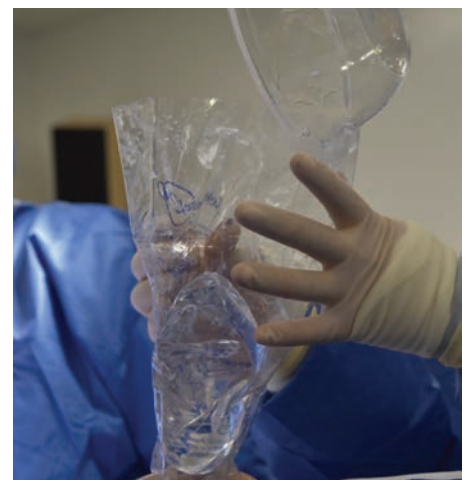

Figure 4 - A vertical limb of approximately 7 cm is created.

STRUCTURAL MASTOPEXY

3-D RESTORATION OF BREAST FORM



JOHN Q. COOK, MD - UNITED STATES

A wide variety of mastopexy techniques exists. Surgeons and the public often categorize these by the appearance of the external scars: peri-areolar, classical “anchor,” vertical “lollipop,” or “L” scars. What occurs beneath the surface is more important. I will share my experience with the structural technique, which I have employed for over ten years. The technique is a refinement of the pioneering work of Dr. Ermete De Longis.

CHALLENGES OF THE PTOTIC BREAST

The ptotic breast presents the plastic surgeon with several technical challenges. In order to achieve a truly pleasing and durable result, the mastopexy operation must be conceptualized as more than a mere “lift.” From the patient’s perspective, restoration of a pleasing upper pole contour is often as important as the restoration of breast position. For this reason, some surgeons routinely place implants with their mastopexies in order to avoid the recurrence of a hollow upper pole when the breast “bottoms out.” Many patients do not want the breasts to be larger and would prefer to avoid potential long-term issues of breast implants.

Often the forces of pregnancy and weight fluctuation have weakened the skin to the point where simple skin brassiere techniques will not hold the breast in a good position. Also, the breast structure tends to splay and widen, and the inframammary fold drops to a low position.

ADVANTAGES OF THE STRUCTURAL TECHNIQUE

The structural technique provides several key advantages. No scars are present at the medial aspect of the breast, which allows the patient to wear a variety of swim suits and clothing styles. The breast is anchored at several levels, rather than relying on only the skin to provide the lift. Breast tissue from the lower central portion of the breast is shifted to the upper portion of the breast and anchored securely in place, providing an auto-augmentation and avoiding the use of implants. The technique also allows the surgeon to reset the inframammary fold level, restore a compact breast structure, and narrow the base width of the breast.

We have found the technique to be applicable to a variety of breast operations: mastopexy, augmentation-mastopexy, reduction, and revision surgery.

FUNDAMENTALS OF THE STRUCTURAL TECHNIQUE

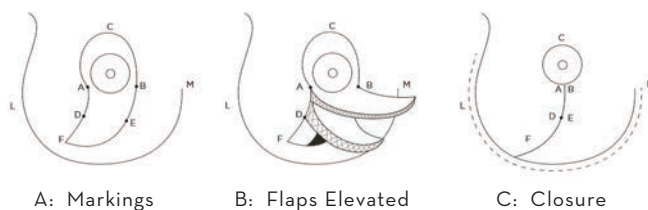


Figure 1 - Fundamentals of the Structural Technique.

The position of the inframammary fold is marked and measured with the patient standing; if the fold has been inferiorly displaced, the true position is simulated and marked. A line is drawn along the midline of the breast, and point C (2 cm above the true inframammary fold) is marked on this line, which corresponds to the location of the superior border of the areola. The peri-areolar skin is now pinched to determine the location of points A and B, which will correspond to the 6 o'clock position of the areola. A pleasing curve is drawn that includes these 3 points. Next, the breast tissue is displaced medially and laterally, and points D and E are marked where the tissue overlies the midline. Point F is then marked where the incisions will end laterally at the new higher level of the inframammary fold; this is typically at least 2 cm higher than the existing fold.

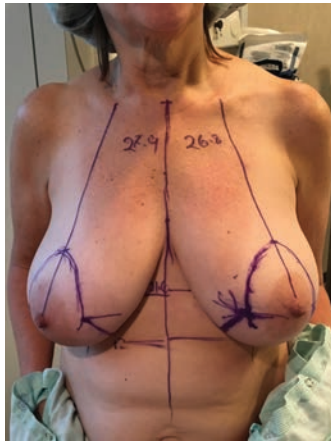

Figure 2 - Patient Markings.

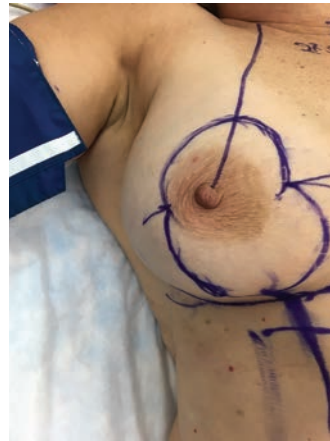

Figure 3 - Markings from Below.

In the operating room, a tourniquet is placed around the base of the breast, the areola is marked typically with a 4.2 cm marker, and the tissue is deepithelialized.

A superiorly based dermoglandular flap is now raised starting at point F and continuing to the base of the areola. The breast tissue beneath the dermoglandular flap is freed medially, laterally, and inferiorly and raised off the subglandular plane so that it maintains a blood supply from the areolar zone.

Undermining continues beneath the rest of the breast structure with preservation of medial and lateral attachments to protect nerves and vessels. The flap of breast tissue can now be easily transposed beneath the upper portion of the breast.

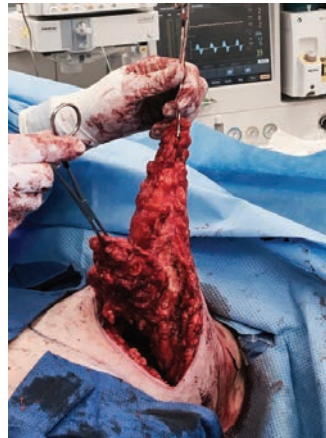

Figure 4 - Dermoglandular Flap Elevated.

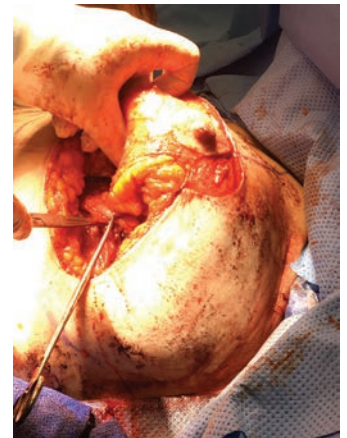


Figure 5 - Dermoglandular and Structural Flaps Elevated.

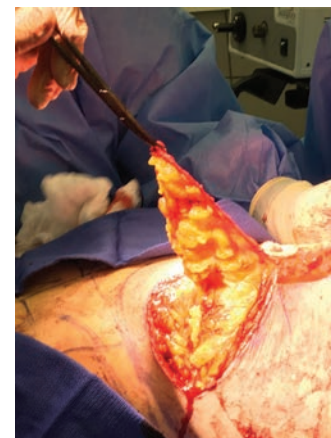

Figure 6 - Dermoglandular Flap Anchored through Pectoralis secures Structural Flap beneath Upper Pole.

The dermoglandular flap is passed through a slip of the pectoralis muscle and sutured in place and several additional sutures help to hold and shape the breast tissue flap in its new position.

The medial and lateral pillars of breast tissue are sutured together, which forms a compact structure with the transposed flap beneath.

An inflection point is chosen that allows for the conversion of vertical excess to horizontal excess, and this sets the level of the new inframammary fold. Tissue beneath the new fold is reduced in thickness through a combination of direct excision and liposuction.

Continued on page 44

Closure is completed in the usual way. Drains are rarely if ever used.

Postoperative care consists of a protective dressing for 3 days; then a support bra.

CLINICAL APPLICATION OF THE STRUCTURAL TECHNIQUE

The technique can be used for a variety of operations including mastopexy, augmentation-mastopexy, small to medium reductions, and breast revision surgery. The breasts hold their position and shape quite well, and patients are pleased with the natural soft fullness in the upper pole.

The procedure is well-suited for many patients who originally had large implants and who want to downsize the implants or remove the implants entirely. The choice of this technique for these circumstances requires an accurate assessment of the remaining natural breast structure.

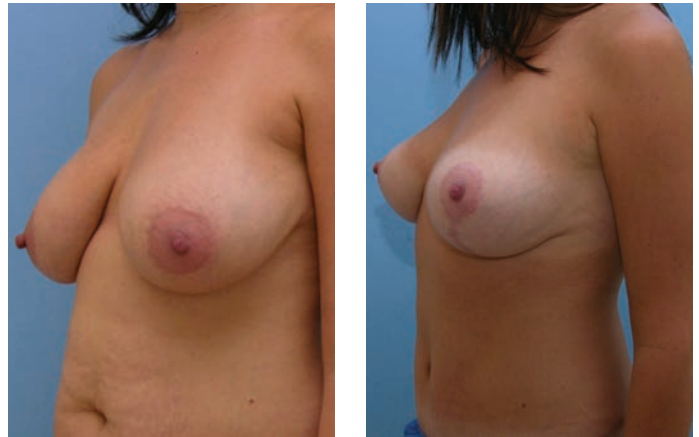

Figure 7 - Structural Mastopexy combined with Abdominoplasty.

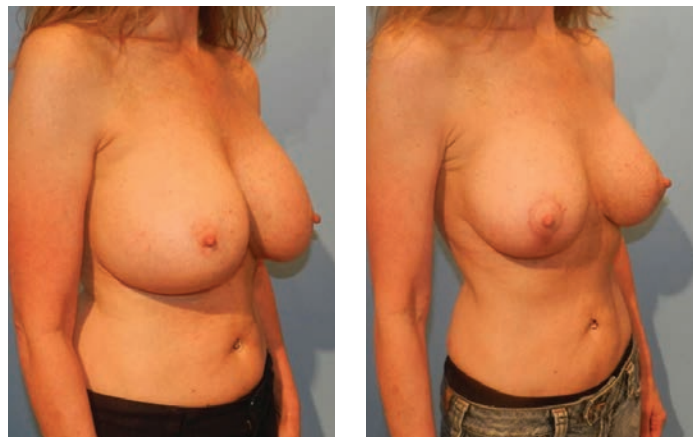


Figure 8 - Structural Mastopexy combined with Implant Downsizing.

GLOBAL PERSPECTIVES: FUTURE THEMES

September 2019: Periorbital Rejuvenation

Deadline: July 15

December 2019: Non-Invasive Fat Reduction

Deadline: October 15

To contribute an article of 500-750 words, please forward it to ISAPS@isaps.org with the subject line: ISAPS NL Series. This should be a non-referenced opinion piece of several paragraphs giving your observations and perspectives on the topic. What do you do in your practice? What unique approaches do you use? What do you see your colleagues doing in your country or region? Photos are welcome, but must be high resolution JPG files attached, not embedded in your article. Please include photo captions.

Articles must be submitted as WORD documents.

A TECHNIQUE OF AUGMENTATION MASTOPEXY

THAT SPARES THE ABDOMINAL PART OF THE PECTORALIS MAJOR MUSCLE



VADIM N. ZELENIN, MD, PHD - RUSSIAN FEDERATION



NIKOLAI V. ZELENIN, MD - RUSSIAN FEDERATION

Introduction and Aims

It is a difficult task to increase the breasts' volume, improve their shape, and lift them to a higher position on the chest because in patients with breast ptosis, the skin envelope has been compromised and doesn't hold the implant in position as tightly as required to properly secure the implant. All this makes augmentation mastopexy one of the most challenging of all the aesthetic procedures.

An aim of this study was to develop a new method of augmentation mastopexy where the stability of an implant's position is provided by sparing of the abdominal part of the pectoralis major muscle.

Patients and Methods

From 2011 to 2017, the authors operated on 65 patients with breast ptosis. In all cases, during the pre-op visits, nipples were located from 1 to 3 cm below the inframammary fold, and the distance from the nipple to the inframammary fold measured under maximal stretch (N:IMF max stretch) was 10.6ffl1.9 cm. Certain asymmetries in the volume of the breasts, in their location on the chest

wall, and in the degree of ptosis as well as asymmetry of the nipple-areola complex, were observed in 56 of the 65 patients. Not one of our patients had massive weight loss.

In all cases, breast augmentation with silicone implants and mastopexy according to the developed technique were performed as a one-stage procedure. The authors' approach is based on two considerations. First, in order to provide support for the implant against gravitation and to prevent its displacement in an inferior and lateral direction, we spare the abdominal part of the pectoralis major muscles. Second, as the mammary gland parenchyma, which has dropped below the inframammary fold, cannot be properly repaired, we elect to remove it.

Selection of the implant's shape and size is based on the measurements of the patient's chest. The implant's height is determined by the distance from the upper border of the 6th rib to the estimated upper border of the breast, which usually corresponds to the fold formed by the lower edge of the pre-axillary fat. The maximal width of the implant is defined by the distance from the m. pectoralis major attachment to the sternum to the outer edge of m. pectoralis major at the estimated nipple location. The projection of the implant depends of the patient's desire to have a bigger or smaller breast size. The volume of implants in our patients ranged from 200 to 350 ml. The average was 280 ffl 15 ml.

Continued on page 46

Anatomically shaped implants were used in the majority of cases (42 against 23). Post-op visits were scheduled at 1-, 3-, 6-, and 12-month intervals and follow up for every patient was at least one year.

Results

There were no major complications in the immediate post-op period. In the late post-op period, all the patients showed stable position of the implant against the submammary fold and were satisfied with the outcome.

We did not observe cases of implant malposition, loss of nipple sensation, wound healing problems, hematoma, seroma, asymmetry, or capsular contracture. The qualities of scars were good and there were no cases of scar widening, hypertrophy and areolar widening. In some cases, with severely decreased elasticity of both skin and parenchyma after six months, we could find some recurrent mammary pseudoptosis which however did not progress and did not bother the majority of patients. Four of the other patients required additional skin and subcutaneous tissue resection in the lower pole at 6-, 7- and 8-months post-op under local anesthesia. This helped to remove the excess of tissue at the lower breast contour.

One of the mastopexy patients received round implants of 200 cc; however, despite a good surgical outcome, after 1.5 years she insisted on having the implants replaced by bigger ones (350 cc) with anatomical shape. The surgery was performed without complications. The abdominal portion of m. pectoralis major and its attachment at the upper edge of the 6th rib could be clearly identified.

The most important precondition for a stable result of augmentation mastopexy is to ensure the implant's stability. It is essential to support the implant against gravitation. The use of a support provided by nature, which is the abdominal part of m. pectoralis major and its attachment provides the implant a stable position on the chest which prevents its displacement downwards and outwards.

This technique is simple and it neither increases the time taken to perform the surgery nor makes the surgery more complicated.

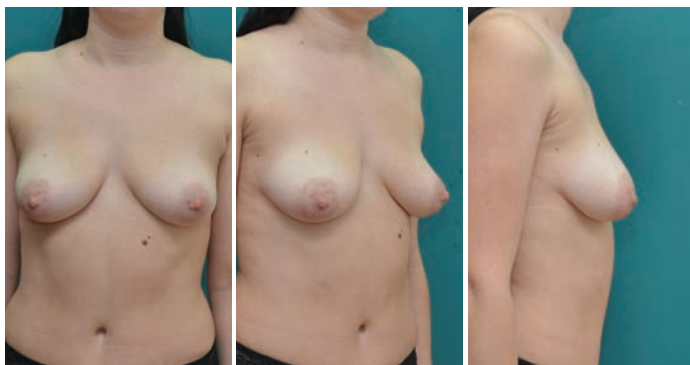


Figure 1 - before

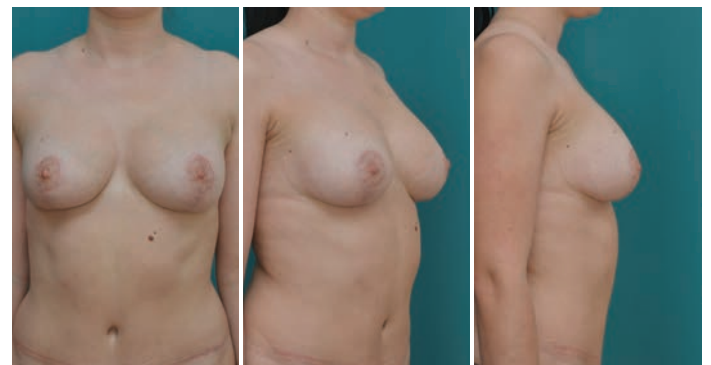


Figure 2 - 1 year after augmentation mastopexy (anatomical implant 270 cc).

FIXED POINT

A TECHNIQUE MASTOPEXY



ALAN SERURE, MD - UNITED STATES



ALAN MATARASSO, MD - UNITED STATES



OBAID CHAUDHRY, MD - UNITED STATES



RENEE GASGARTH, MD - UNITED STATES



ANSON NGUYEN, MD - UNITED STATES

Mastopexy is a common procedure in women complaining about breast ptosis. This can be the result of postpartum changes, aging, massive weight loss or in young females with poor tissue characteristics. However, it is paramount to reconcile patient expectations with potential unfavorable outcomes such as bottoming out or visible scars. Revisions and litigation can be with present with this procedure, especially when combined with augmentation. Despite this, a well-planned and executed mastopexy will lead to favorable outcomes and high degree of patient satisfaction.

Patient History and Physical Findings

A thorough history and physical exam are required for each patient, with special attention to patient age, weight fluctuations, pregnancies, breast feeding, use of medications, and overall goals (lift versus mastopexy augmentation). Any personal or family history of breast pathology should be noted. We recommend patients

over the age of 40 all have mammograms prior to surgery. The physical exam should focus in on the overall quality of breast skin, including stretch marks and elasticity. Measurements of the sternal notch to nipple distance, nipple to inframammary fold (IMF), asymmetries, volume, base width, nipple and areolar size, and most importantly, the degree of ptosis, based on Regnault classification should be noted.

Surgical Markings/Technique (Figures 1-3)

Surgical markings for mastopexy patients are considered the most important aspect of the operation. The markings should be verified multiple times with the realization that it is the roadmap to a successful outcome. Should the markings be incorrect, the surgery will be compromised.

The following landmarks are drawn for all mastopexy operations, regardless of excision pattern, and markings for each skin excision pattern are described below:

1. Breast meridian is drawn.
2. The inframammary crease is marked.
3. The superior aspect of the new areola position is the fixed A point predetermined at the time of marking.
4. The new nipple position is marked at or 1 cm above inframammary crease.
5. The final skin excision is "tailor tacked" based on volume and skin elasticity.

Continued on page 48

6. A round template “cookie cutter” between 38 and 50 mm is used to circumscribe the areola.

Of note, point ‘A’ is never changed.

A. Circumareolar mastopexy (Figure 1) - This technique may be employed in patients with mild ptosis who require only a minimal lift.

1. The new nipple position is placed at or just above (1 cm) the inframammary crease.
2. The extent of areola and skin to be resected is determined by tailor tacking an oval excision between A (new location of superior aspect of the areola) and B₁ and B₂ in the operating room.
3. The new superior aspect of the areola is fixed point A.
4. The existing top of the areola is A₁.
5. B₁ and B₂ are the lower lateral extension of the skin excision.

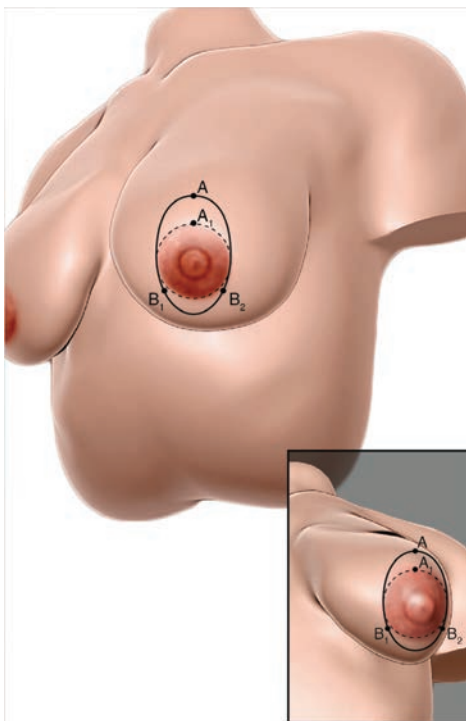


Figure 1

B. Vertical “lollipop” mastopexy (Figures 2-3) - The “lollipop” pattern can be considered in patients with moderate to severe ptosis with significant laxity in the vertical dimension. A reasonable lift can be achieved with this approach in a significant portion of patients.

1. Mark the landmarks as described above.
2. A is the position to which the areola will be raised.
3. A₁ top of areola.
4. B₁ and B₂ are the lower aspect of the elliptical excision. C is the center of the inframammary crease and the inferior aspect of the elliptical skin excision. C should not be more than 1 cm lower than the inframammary crease.
5. As in all mastopexy procedures, final skin excision is tailor tacked based on skin elasticity and breast volume.

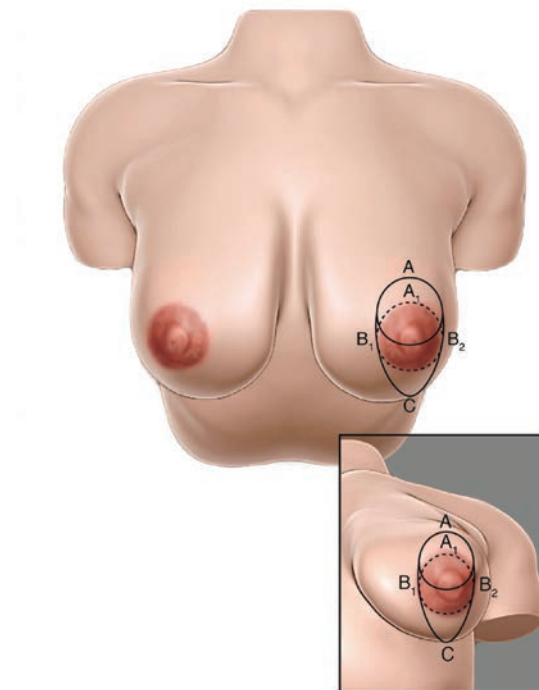


Figure 2

C. Wise pattern full mastopexy (Figure 3) - This technique is reserved for patients with significant laxity in the vertical and horizontal dimension, such as in massive weight loss patients.

1. A modified wise pattern is employed placing the center of the keyhole at the level of the inframammary crease.
2. A is the fixed point to which the areola is elevated and A₁ is the top of the areola.

3. The superior aspects of the vertical limbs are B1 and B2. The lower aspects of the vertical limb (length is between 5-6 cm) is are C1 and C2.
4. D1 and D2 are the lateral aspects of the inframammary crease. D1 and D2 are never more medial or lateral than the “shadow of the breast.”
5. The width of the vertical limbs distance between B1 and B2 to C1 and C2 is adjusted to completely excise the areola skin and appropriately tighten the lower pole.

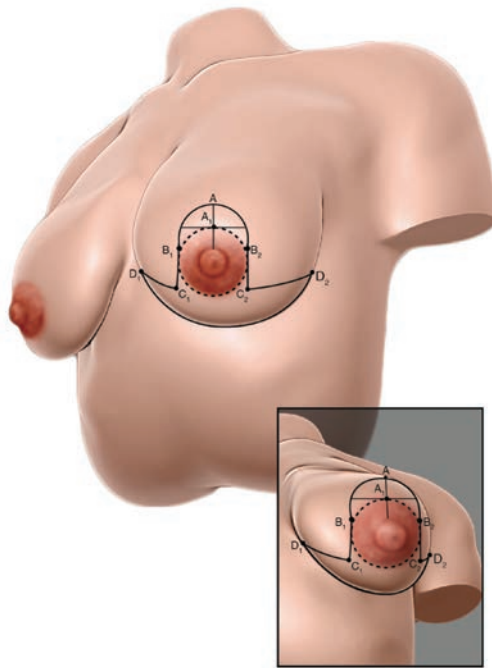


Figure 3

All incisions are closed with absorbable sutures in a standard fashion. The nipple areolar complex is inset with either absorbable sutures, or a combination of absorbable and percutaneous monofilament sutures, based on surgeon preference. A permanent PTFE suture placed in a “wagon wheel” fashion can be undertaken to offset tension, especially in circumareolar approaches with implants.

It is up to the surgeon to employ the pattern based on comfort level and on patient specific characteristics. At times, one may utilize an autoaugmentation approach,

where a pedicle flap is used to augment volume with each mastopexy. This may moderately increase the size of the breasts and is an alternative for patients not desiring implants. In other instances, the ptotic lower pole of the breast can be excised. Should augmentation be performed in conjunction with mastopexy, it is the author’s preference to only use smooth round implants.

Postoperative Care

Patients are placed in a soft, supportive bra without an underwire for 2-3 weeks, or longer. Dressings are removed in 24 hours, and gradual return to normal activities can be anywhere from 4-6 weeks.

Conclusion

The desire for a lifted, youthful breast will always remain among women, and it is important to address their unique concerns, desires, and limitations to formulate a surgical plan. A variety of techniques have been described for a mastopexy procedure, and each method has its own strengths and drawbacks. It is imperative for the surgeon to be comfortable with all types in order to provide each patient with the best possible outcome based on their characteristics and goals.

References:

- Matarasso, A., Wallach S., Rankin, M. “Reevaluating the Need for Routine Drainage in Reduction Mammoplasty.” *Plastic and Reconstructive Surgery*. 102(6):1917-1921, 1998.
- Matarasso, A., Serure, A. Book Chapter: “Breast Augmentation Mastopexy”. *Cosmetic Breast Surgery*. Editors C. Bob Basu and Sameer Patel. Thieme Publishing. (in press)
- Weichman K, Doft M, Matarasso A. The impact of mastopexy on brassiere cup size. *Plastic Reconstructive Surgery*. 2014 Jul;134(1):34e-40e.



NEXT GENERATION MASTOPEXY

HUGO D. LOUSTAU, MD - ARGENTINA

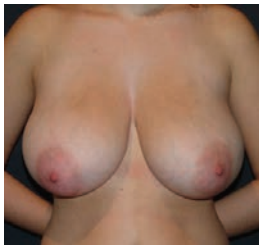

Figure 1

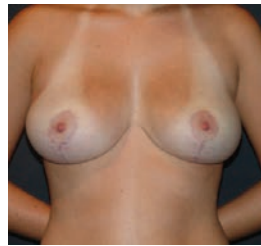


Figure 2

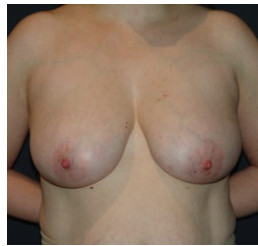

Figure 3

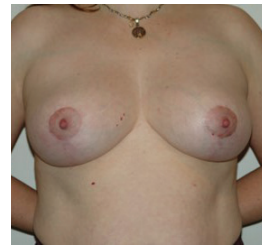

Figure 4

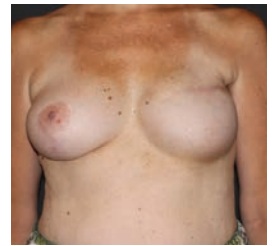

Figure 5

From a chronological point of view, the initial techniques in mastopexy focused on maximal skin resection from the lower pole. The study of Sara Zehm (APS 2012) shows that elongation of the distance between the areola and inframammary fold (IMF) is an inevitable outcome with the inverted T technique.

The author's advice is to place the new NAC at the level of the IMF with a distance from the IMF to areola that does not exceed 4 to 4.5 cm, with a tight closure of the vertical component.

From Marchac onwards, we learned techniques that resected more skin from around the areola. In my opinion, the circumvertical or short horizontal scar seems to best preserve the shape of the breast. In my experience, one of the most valuable instruments to a successful outcome is a significant skin resection around the areola and in the base of the breast, as was suggested by Ramirez (PRS 2002 109 (2)512-522) (**Figures 1 & 2**).

Further, the addition of an inferior pedicle such as the one described by Ribeiro (PRS 2002 110 (3)960-970) helps to relocate volume to the upper pole and makes the result more stable.

My first combination of Ramirez and Riveiro's techniques, a pure breast pexy, one year after surgery (Loustau APS 2008) (**Figures 3 and 4**).

The inferior deepitelized pedicle, sutured to the pectoralis major provide volume and projection to the areola and upper pole. Two years after surgery, there is almost no variation in terms of shape (Figure 5).

My toolbox to avoid bottoming out and achieving stable-shaped breasts in mastopexy includes:

- ✓ Greater skin resection around the areola
- ✓ Areola located not too high
- ✓ Short and tight vertical scar
- ✓ Short horizontal scar
- ✓ Inferior deepitelized pedicle attached to the pectoralis major. (Type I Ribeiro's)

Of course, further studies will be needed to confirm the present clinical observation.

LATERAL TO MEDIAL TENSION MASTOPEXY



PHILIPP FALLSCHEER, MD - SWITZERLAND

Introduction

Mastopexy is one of the most common aesthetic surgical procedures performed worldwide. The main target of this treatment is a reduction of the redundant skin as well as an improvement of the shape and a repositioning of the nipple-areolar complex.

The development of modern mastopexy techniques has evolved hand in hand with innovations in breast reduction surgery. Numerous advancements have been described, including the use of various types of meshes to hold the breast, including slips of pectoralis muscle to support the breast. Despite the advancements in the field of mastopexy, there still remain many challenges for the future.

Most of the techniques do not adequately deal with the problem of excessive tissue in the back and the infra-axillary area, which is often an issue in patients with severe ptosis.

It's our belief that most of the techniques currently used do not properly allow us to raise or fix the infra-mammary fold and also, they often do not allow an accurate design of the shape of the breast. With our technique we aim to solve this problem with a major tissue transfer.

Methods and patient selection

Preoperative markings are performed with the patient standing. The main markings are performed as in the drawing (Figure 1).

The operation is performed with the patient in a semi-sitting position and the arms in abduction. Tourniquet at the base of the breast. Areolar punch of 38 mm diameter.

Superficial (epidermal) peri-areolar incision and deep (transdermal) of the rest of the markings (excluded on DB'). De-epithelialization of the stem and triangle DB'E.

Breast mobilization starting from the sub-mammary fold in a cranial direction on the pre-pectoral plane. Excision of the breast tissue from the lower pole, leaving all possible subcutaneous tissue (but not the gland) under the dermo adipose triangular flap. Wide lateral subcutaneous mobilization when needed in severe ptosis.

The dermo-adipose flap is pulled laterally and medialized by advancing the lateral thoracic tissue fixed in the anterior axillary line with two or more Vicryl O stiches. The lower margin of the triangle is fixed along the new inframammary fold to the fascia below the inferior border

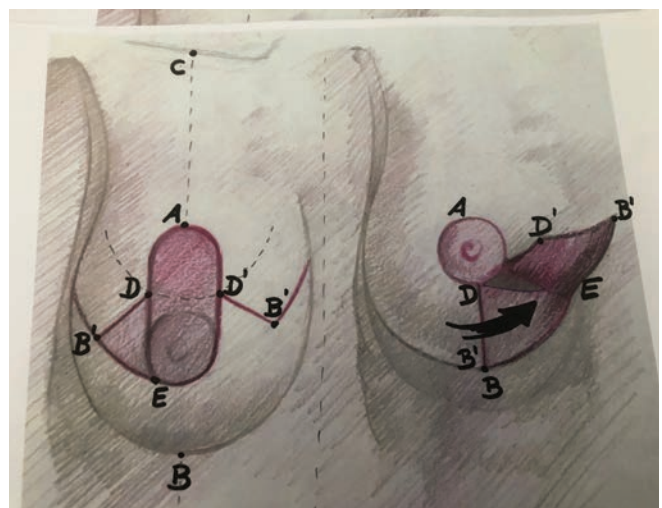


Figure 1 - Pre-operative markings.

Continued on page 52

of the pectoralis major muscle. The outer point (E) of the flap is fixed to the pectoral fascia at the height of the fifth rib in the parasternal area. A drain is inserted.

The remaining medial skin flap is progressively decreased and thinned towards its medial extremity D'B" and fixed above the dermo adipose flap closing the vertical incision. Peri-areolar and inframammary closure with absorbable intradermal sutures.

Ideal indications for this type of intervention are: lateral thoracic excess of skin and important cutaneous ptosis, as in cases of post-bariatric surgery, mastopexy after removal of breast implants, desire for strong breast projection and volumetric filling of the cleavage, redefinition and stabilization of a marked inframammary fold, complex secondary interventions with asymmetry.

This technique can be performed with the classic inverted T incision but also strictly vertical (modified) incision in cases of moderate skin excess. It is also possible to carry out this operation with implant augmentation. In cases of capsulectomy with mastopexy it is possible to raise this dermo adipose triangular flap and use it as coverage tissue in the lower pole.

Results

We have performed this operation since 2010 with a high degree of patient satisfaction (**Figure 2**)

Discussion

The proposed technique has advantages, disadvantages and limitations. The main advantages are the possibility to shape the breast optimizing projection and to save tissue which can be used to fine-tune the breast shape.

The technique is based on the concept of avoiding tension on the skin by displacing the tension onto the deep tissue, from lateral to medial. This creates a new stable inframammary fold and a solid lower pole which supports the breast.

With the dermal flap, an excellent bearing of the breast is obtained through an "internal bra." Moreover, in the case of implant insertion, this is covered by two layers of tissue on the lower pole. Thanks to the uniformly distributed mobilization and tension from lateral to medial, the technique allows good recovery of skin and lateral thoracic tissue, which otherwise would remain redundant.

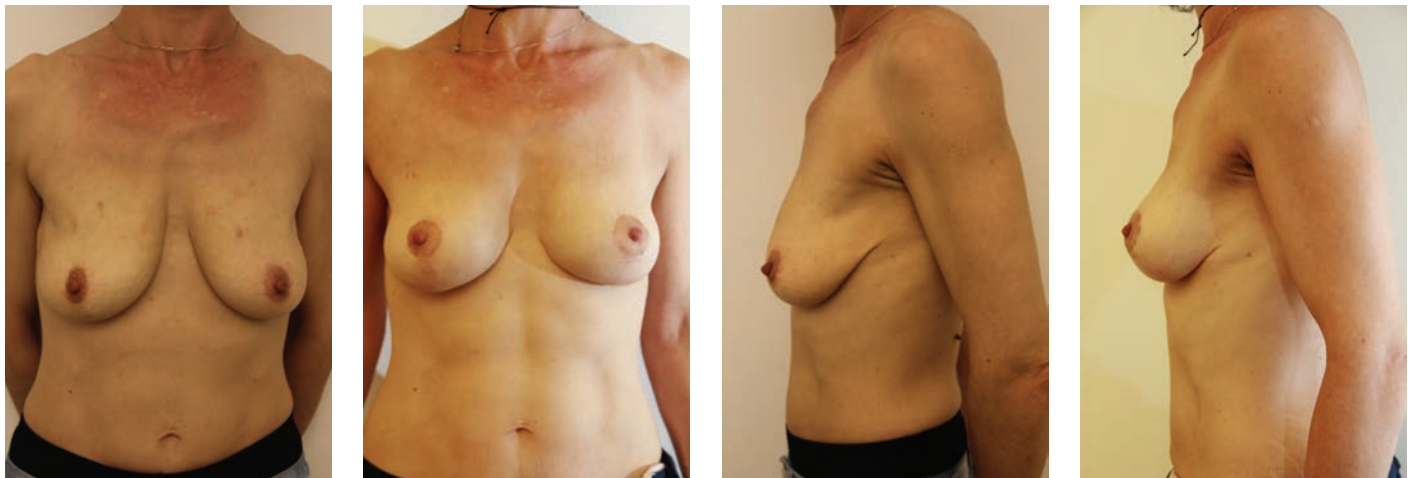

Figure 2 - Pre-operative and 1-year postoperative.

A disadvantage is the duration of the operation. Another disadvantage is the significant mobilization of the lateral tissue in severe cases and fixation to the chest wall may lead to postoperative pain in the first few weeks.

Conclusion

We believe this technique is an effective alternative to other well described cranial pedicle procedures suitable for mastopexy, or revision surgery. We consider it adequate to meet the current needs of increasingly demanding patients. It allows us to obtain very predictable results over time, even with considerable bodyweight variations, and preserves the ability to breastfeed.

In our experience with this technique, we believe to have achieved satisfactory breast position and shape, as well as good quality of scars.

The concept of this technique is based on the new formed and very fixed inframammary fold and pole on which the breast is placed and successively shaped, guaranteeing quite a predictable outcome.

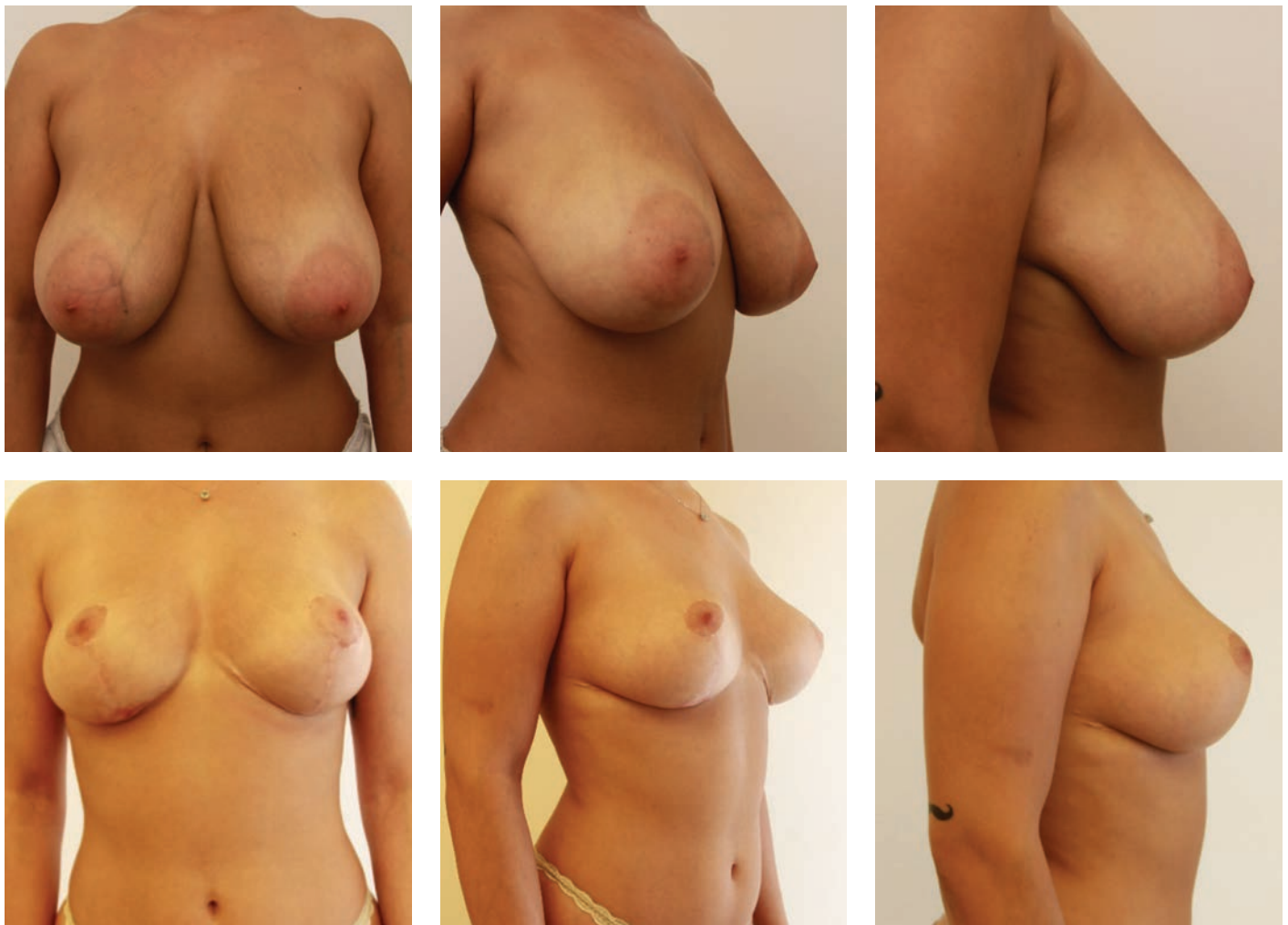

Figure 3 - Pre- and 1-year postoperative mastopexy for aesthetic reasons in addition to glandular reduction.

SECONDARY AUGMENTATION MASTOPEXY:

THE ULTIMATE CHALLENGE



GIANLUCA CAMPIGLIO, MD, PHD - ITALY
ISAPS Second Vice President

According to many distinguished plastic surgeons, augmentation mastopexy is considered one of the most difficult procedures in aesthetic plastic surgery. In the past, some of them even suggested to perform it in two separate stages, but in my personal opinion this is no more viable to our patients.

The main reason of this intrinsic difficulty is the fact that augmentation mastopexy is in reality the combination of two contradictory operations performed at the same time on the same patient: augmentation (increasing of the breast volume with enlargement of its base) and mastopexy (reshaping of the breast cone with reduction of its base). The two procedures also heal very differently in the post-operative period and this certainly can contribute to increasing the complications rate.

I think that another critical issue is the pre-operative planning of the mastopexy as an accurate drawing is not easy. Indeed, if the mastopexy is marked before the operation, with the patient standing in front of the surgeon, the designs are not appropriate as parameters will change once the implant is inserted, especially if of large volume; on the other hand if the mastopexy is planned after the implant, this is done with the patient lying on the operating table and that is not ideal considering the force of gravity.

After a long learning curve, my preferred current option is to make a very simple drawing, marking only the two breast meridians and the inframammary folds. I subsequently perform my breast augmentation and then I simulate the mastopexy on both sides using staples and stitches. Only when I am totally sure of the symmetries between the two breast cones do I perform the resection of skin (and gland if necessary).

This approach works very well for the primary cases and allows me to obtain satisfying results even if the revision rate for augmentation mastopexy is still the highest in my practice. Things are even tougher if we consider secondary augmentation mastopexy.

A personal classification distinguishes two types of this operation: type 1 or false type in which patients previously underwent a breast augmentation and after some years develop a ptosis of the breast parenchyma and/or of the implant (**Figures 1-2**); and type 2 or true type in which patients show some aesthetic defects of the breast after a previous augmentation mastopexy (**Figure 3-4**).

Considering this last category, the most common situation is when a patient who needs a surgical revision because of the poor quality of the scar (mainly the peri-areolar) or because of recurrence of breast ptosis due to relaxation of the tissues. The operation is usually simple and can

be done under local anesthesia and sedation. Much more difficult is to redo the mastopexy and change the implant at the same time. Indeed, in these cases nipple and areola viability is at risk due to the previous and new incisions and undermining has to be limited and conservative. Also, the presence of scars and tissue deficiencies from the precedent mastopexy can often be a difficult problem to manage. In order to simplify the procedure, reduction of the volume of the breast implant can be useful as this helps to recruit new skin but usually it requires a complicated capsulorrhaphies if the plane of the pocket is not changed.

In conclusion primary augmentation mastopexy is a difficult procedure, but the (true) secondary procedure is a big challenge even for the experienced surgeon.

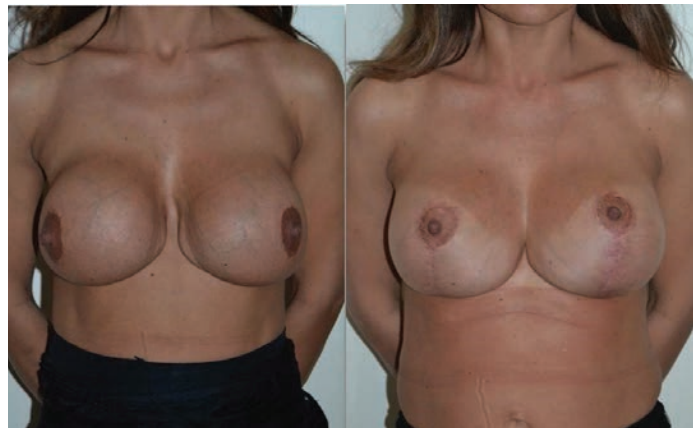


Figure 3 - Type 2 or true secondary case: ptosis of the gland and of the subglandular implant with asymmetrical lateral malposition of the nipple-areola complex. In the medial regions two big dog ears can also be seen. The operation consisted in implant exchange and capsulectomy, change of the plane of the implant from sub-glandular to sub-pectoral and secondary mastopexy.

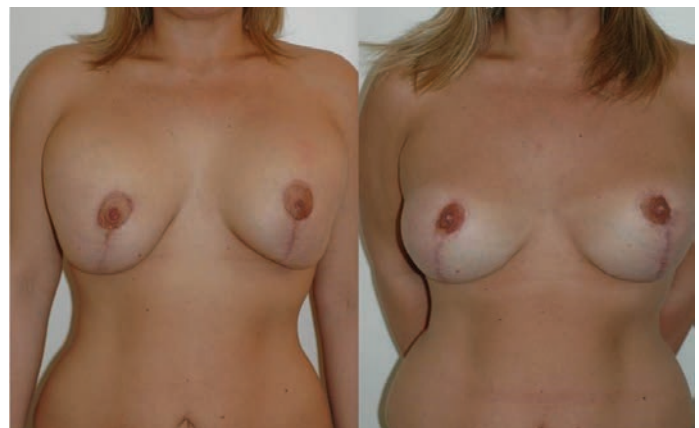


Figure 4 - Another example of Type 2 or true secondary case. In this patient a disproportioned breast implant was positioned very high in a sub-pectoral pocket. With time the gland fell in front of the prosthesis causing the so called "waterfall deformity". Surgery consisted in implant exchange with a new smaller device, lateral capsulorrhaphy and inferior capsulectomy, secondary mastopexy.

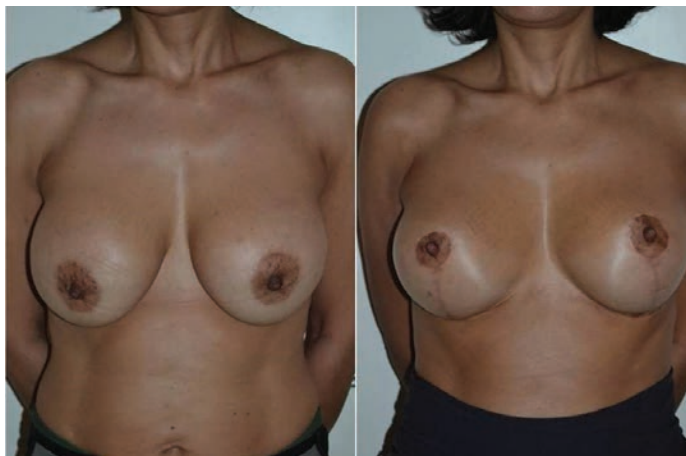


Figure 1 - Type 1 or false secondary cases: implant exchange and capsulectomy, change of plane of the implant pocket from sub-glandular to subpectoral and superior pedicle mastopexy.

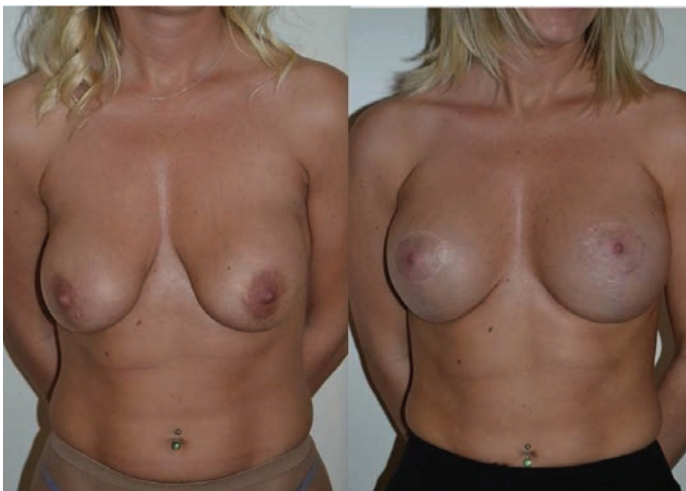

Figure 2 - Another example of Type 1 secondary case. The patient has been treated in the same way as patient of figure 1.

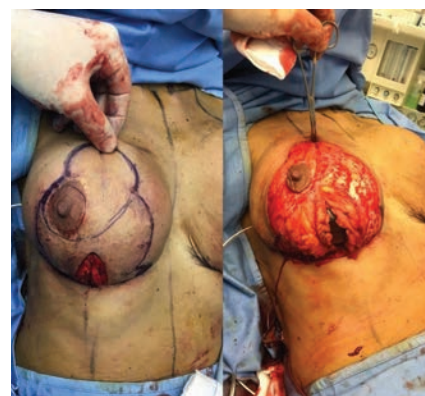

Figure 5 - Intraoperative pictures of the case in Figure 3. The pattern of skin reduction had to be tailored considering the medial and superior repositioning of the nipple areola-complex. In these cases, once removed the skin, dissections and undermining should be minimal in order to preserve better the nerve and blood supply to the areola, especially in cases like this where the patient was coming from abroad and had no clinical documentation of the previous surgeries.

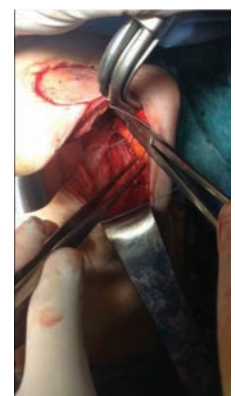


Figure 6 - Intraoperative detail of the case in Figure 4. Lateral capsulorrhaphy is performed with a double row of running non absorbable braided suture and its purpose is to reduce and reshape the implant pocket.

CURRENT TRENDS IN MASTOPEXY



FRANK AGULLO, MD, FACS - UNITED STATES

Mastopexy is one of the fastest growing procedures as either a stand-alone procedure or concomitant with breast augmentation or reduction. Many surgical techniques have been developed over the last decades and have substantially contributed to the evolution of aesthetic breast surgery. However, not every technique is suitable for all breast types, and there is the continuing challenge of maintaining symmetry, the position of the nipple-areola complex, and fullness of the upper pole. Predicting the amount of skin stretch and breast dropout long-term has proven to be the most challenging. Surgeons frequently tighten the skin envelope and lift the parenchyma; however, the stability of the surgical result is variable due to the poor tissue which led to ptosis in the first place.

To reduce the variable of skin and tissue stretch, a mesh can be incorporated to support the breast. The use of mesh has been well described in the literature. Most recently, Adams and Moses described their experience with central mound mastopexy and the use of a poly-4-hydroxybutyrate resorbable scaffold for lower pole support and reported stable results at one year without significant complications. Previous studies have also shown that mesh does not interfere with the physical examination of the breast, nor does it interfere with radiographic (mammography), ultrasound, or magnetic resonance imaging.

In my practice, I have incorporated the use of a three-dimensional poly-4-hydroxybutyrate resorbable scaffold with a reinforcing rim (Galaform 3D, Galatea Surgical, Lexington, MA, USA) to support the central mound using a central pedicle technique for mastopexy with or without reduction for the last three years. The material has a unique long-term resorption profile of 12 to 18 months, a monofilament construction, and some elasticity that mimics human tissue (**Figure 1**).



Figure 1 - Three-dimensional poly-4-hydroxybutyrate resorbable scaffold with a reinforcing rim.

A full Wise pattern is my preference in order to shorten the nipple to inferior mammary fold (IMF) distance and avoid pseudoptosis. The scaffold is placed to support the

lower pole of the breast, much like a push-up bra or sling, and anchored to the pectoralis muscle (**Figure 2**). A drain is placed prior to closure and left on average 5-7 days or when serosanguinous output is less than 30 mL in 24 hours for two consecutive days.

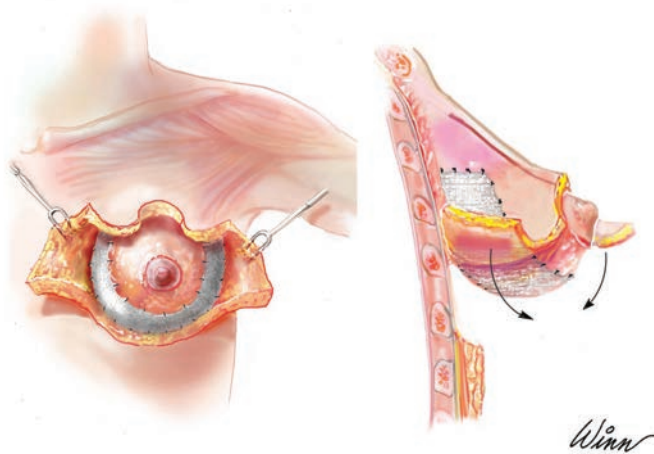


Figure 2 - The scaffold is placed to support the lower pole of the breast, much like a push-up bra or sling, and anchored to the pectoralis muscle.

I have used this scaffold technique in more than 50 patients (**Figures 3-4**). Compared to other scaffolds I had used in the past, I have not encountered problems with delayed scaffold integration, extrusion, or infection. No cases with seromas or other significant complications were encountered related to the use of the scaffold.

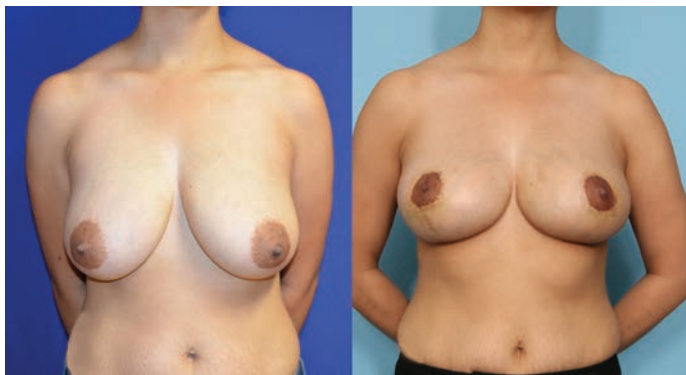

Figure 3 - 31-year-old patient two years after a central mound mastopexy with scaffold support.

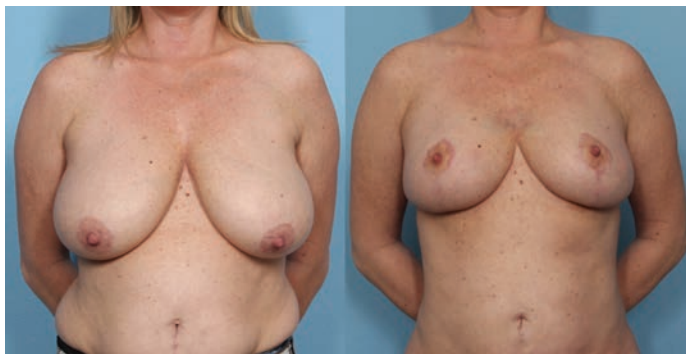

Figure 4 - 43-year-old patient two years after a central mound breast reduction with scaffold support.

The scaffold proves useful in augmentation mastopexy cases by supporting the implant inferiorly in a submuscular placement. The scaffold is secured inferiorly to the IMF, and superiorly to the pectoralis muscle, this removes the burden of the added weight of the implant to the breast tissues. The stability of the procedure is demonstrated in Figure 5 from one month to three years despite weight gain. There is usually a predictable lower pole stretch of 1-2 cm during the first three months, which then stabilizes.

The scaffold has the advantage of being significantly less expensive than biologic acellular dermal matrices. The added cost of the scaffold has been a deterrent to some patients that have opted out of the reinforcement. The perceived negative view of anything foreign by some patients has also been a deterrent.

The concept behind using soft-tissue reinforcement in mastopexy addresses the inherent paradox of mastopexy, namely, that the breast is rejuvenated but the skin envelope and tissue used to support the lifted breast are damaged and prone to recurrence and stretch. Using the scaffold, the amount of lower pole stretch becomes more controlled and predictable.

The author has no financial interest in any product of company mentioned in this article.

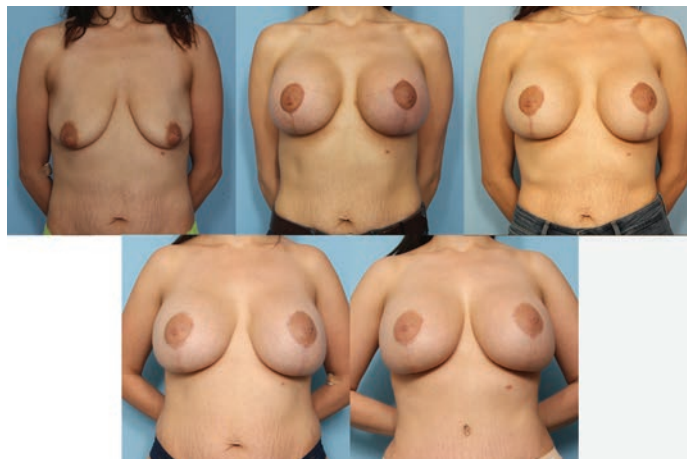


Figure 5 - 28-year-old patient after augmentation mastopexy, 650cc smooth round high profile silicone implant, submuscular placement with scaffold reinforcement, at preop, three months, one year, two years, and three years post procedure (from left to right).



SURG MAR



BISHARA ATIYEH, MD - LEBANON



FADEL CHAHINE, MD - LEBANON

HOW I MARK MY PATIENTS FOR MASTOPEXY

For decades, marking for mastopexy followed the standard Wise pattern design that was easy to execute and to teach. With increasing popularity of the vertical scar mastopexy, surgical planning and incisions marking became mostly free hand as refined and popularized by Lassus and Lejour. When ill performed, it often leads to a poor aesthetic outcome. Moreover, this marking pattern is not without major drawbacks, such as long vertical scars extending below the infra-mammary crease and excessive skin gathering and “dog-ear” at the lower end of the scar that may require long periods for resolution, causing extreme distress to patients and surgeons alike.

Vertical scar marking depends primarily on artistic skills and experience making it difficult to teach to plastic surgeons in training. There was a need therefore to

standardize surgical planning to make the procedure more appealing to young surgeons and make results more predictable.

With the patient in the standing position, a standard Wise keyhole pattern with standard measurements is marked without the elliptical lower component. The initial reference markings are the mid-sternal line extending into the navel, the mid-clavicular point (7 to 9 cm from the sternal notch), the existing sub-mammary creases, and the nipple line breast axis (from the mid-clavicular point down to the nipple, crossing the sub-mammary crease approximately 10 cm from the mid-sternal line). The vertical limbs of the drawing are made to measure 4 cm and their divergence is adjusted as usual depending on the degree of ptosis and the amount of lifting required.

ICAL KING

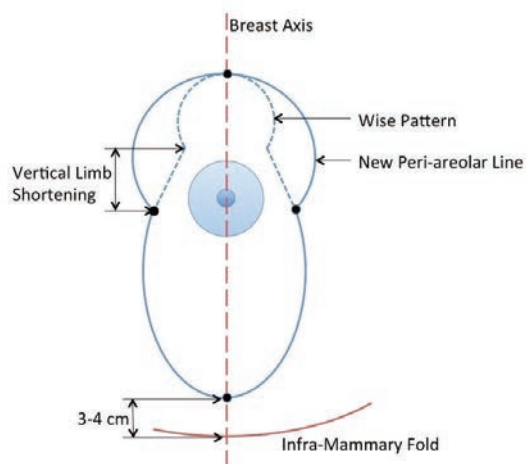


Figure 1 - Diagrammatic representation of mastopexy marking.

for shortening vertical scars. However, the greatest advantage of this pattern is without doubt the fact that it uses standardized drawing techniques easily taught and easily mastered with limited but well guided free-hand drawing. It is applicable to both mastopexy and reduction mammoplasty regardless of the glandular areola pedicle. We are using also the same marking pattern for mastectomy and immediate implant breast reconstruction. It proved to be very versatile and can be adapted to any tumor location and necessary

additional skin excision.

References:

1. Atiyeh BS, Rubeiz MT, Hayek SN. Refinements Of Vertical Scar Mammoplasty: Circumvertical Skin Excision Design With Limited Inferior Pole Subdermal Undermining And Liposculpture Of Inframammary Crease. *Aesthetic Plast Surg.* 2005; 29(6):519-31.
2. Ibrahim AE, Atiyeh BS, Dibo SA, Sarhane, KA, Abbas JS. De-epithelialized Dermal Barrier for a Safe Immediate Prosthetic Breast Reconstruction post Circumvertical Skin Sparing/Reducing Mastectomy (SSM/SRM). *Eur J Plast Surg.* 2012; 35(11): 787-793.
3. Atiyeh B, Dibo S, Zgheib E, Abbas J. Skin sparing/skin reducing mastectomy (SSM/SRM) and the concept of oncoplastic breast surgery. *Int J Surg.* 014;12(10):1115-22.

A semicircular new peri-areolar line is then drawn connecting 3 points: the 2 lower ends of the vertical limbs and the top of the keyhole pattern. On average, the medial portion of this line is 9 to 11 cm from the midline, and the lateral portion is approximately 12 cm from the anterior axillary line. Though the drawing is free hand it is greatly facilitated by pre-determination of the 3 key points. This marking allows more areolar skin excision than the standard Wise drawing. Then with the regular Lejour maneuver, medial and vertical lines are dropped from the ends of the peri-areolar line. With the patient in the supine position, the vertical lines are then connected by a semicircular line the bottom of which is 2 fingers (3-4 cm) above the existing infra-mammary fold at the breast axis line. The marking is finally completed at the operating table by delineating an areola 4 to 5 cm in diameter.

This marking in fact is a circumvertical pattern, a combination of the vertical Lejour and the Binelli “round-block” circumareolar patterns. Although conceptually opposed to the standard vertical design, it allows a greater excision of periareolar skin than the Lejour pattern without excessive periareolar skin wrinkling as seen with the “round Block” technique. The circumvertical modification probably is the most important maneuver

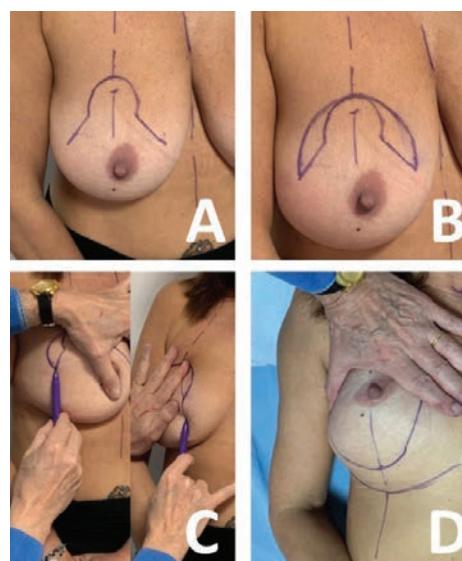



Figure 2 - Marking demonstration. (A) Wise pattern. (B) New peri-areolar line. (C) Vertical line marking with Lejour maneuver. (D) Circumvertical drawing completed.


HOW I MARK: AUGMENTATION MASTOPEXY WITH A SUBMUSCULAR APPROACH IN THE MASSIVE WEIGHT LOSS PATIENT



ELVIO BUENO GARCIA , MD, PHD - BRAZIL



JOANNA GUELLER BECKER, MD - BRAZIL



LYDIA MASAKO FERREIRA, MD - BRAZIL

The massive weight loss patient has some peculiarities that must be considered in the preoperative period. The important laxity of the tissues with loss of support and poor quality of skin associated with ptosis of the breast make this a true surgical challenge.

It is known that these patients have a higher tendency to complications when compared to usual patients. Therefore, the surgeon needs to be careful and know how to mark adequately as a crucial step to the success of the operation.

Breast deformities after massive weight loss can be classified according to the Pittsburgh scale in three levels: (1) light ptosis, suitable parenchyma, and no saggy skin; (2) ptosis grade II or III, saggy skin, light parenchyma atrophy, and no significant deviation of the papillary-

areolar complex (PAC); and (3) a more pronounced deformity, with significant ptosis, saggy skin, intense parenchyma atrophy, and medial deviation of the PAC. This scale is useful to assess the level of deformity and plan appropriate procedures. For this patient, a Grade II of Pittsburgh, an augmentation mastopexy is the indicated approach, with or without implants.

In this female patient, who lost 55 kg, we performed a retromuscular augmentation mastopexy (figures 1A to 1B).

Markings:

The patient is marked in the upright standing position, and the following markings are made (figures 2A to 2E):

- Midline;
- Breast meridian;
- The point A is marked, where A = the new nipple location marked by transposition of the inframammary fold onto the front of the breast, at the level of the meridian. The superior limit of the areola is marked 1.5 cm above the new nipple position;
- A line from the sternal notch to point A is marked to ensure symmetry; and,
- Inframammary fold.
- A maneuver is performed to measure the skin excess of the breast. The breast is displaced, first laterally and then medially. It is important to remember that the implant will be placed and more skin is necessary.
- An equilateral triangle (1.5 cm of side) is drawn on the intersection level of these two lines, as a security

measure in the event of a tight closure at the “T” junction (figure 3). At the end of the procedure, the surgeon may discard or maintain this skin.

- The breast is displaced again, first laterally and then medially. Vertical lines are drawn from the lower portion of the new areola to the inframammary fold laterally and then medially.
- The symmetry of the areola position is confirmed. In this case the distance between the new areola and the midline is 12 cm on each side.

Intraoperative technique:

- The skin is de-epithelialized and a dermoglandular inferior rectangle (8cm of height x 6 cm width) is made in the central part of the breast.
- After the pectoralis muscle release, creation of the pocket and implant introduction, an inferior flap is used to cover and protect the implant (Figures 4A and 4B).
- The back of the bed is rasied for assessment of the previously marked mastopexy. The nipple areola complex is repositioned as needed and the superior pedicle is created. The breast is reshaped and the skin excess is removed. Finally, a suction drain is introduced, and the wounds are closed in layers.

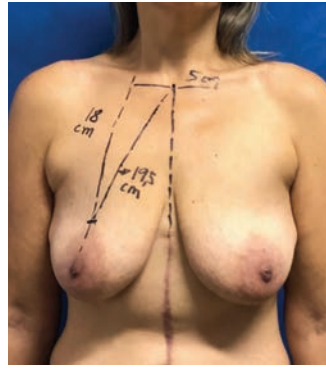

Figure 2A - Initial markings of augmentation mastopexy.

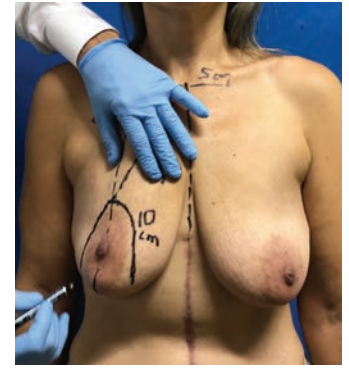


Figure 2B - Markings of augmentation mastopexy.

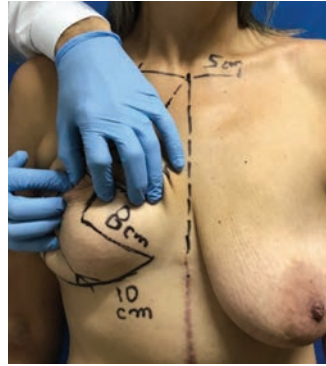


Figure 2C - Markings of augmentation mastopexy.

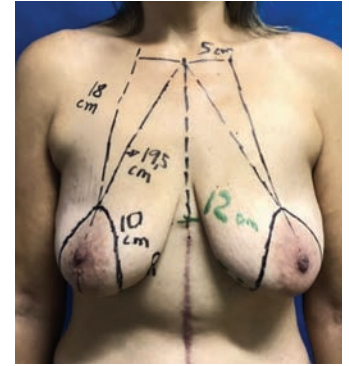


Figure 2D - Final markings of augmentation mastopexy.

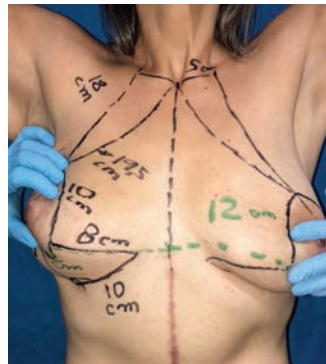


Figure 2E - Final markings of augmentation mastopexy.

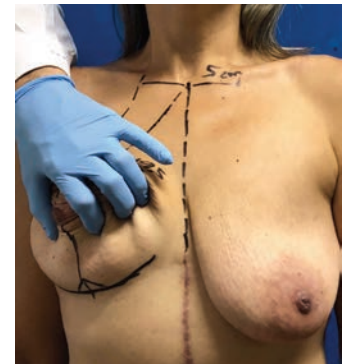

Figure 3 - Markings of an equilateral triangle (1.5 cm on each side) on the intersection level of the meridian breast and the inframammary fold. This is the point of highest dehiscence risk during mastopexy.

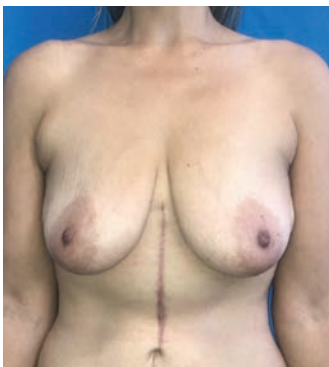

Figure 1A - Preoperative frontal view of a 39-year old female, after massive weight loss (MWL).

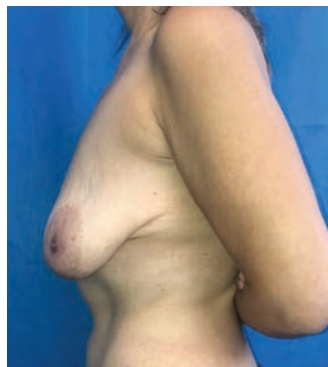

Figure 1B - Preoperative left lateral view of a 39-year old female, after MWL.

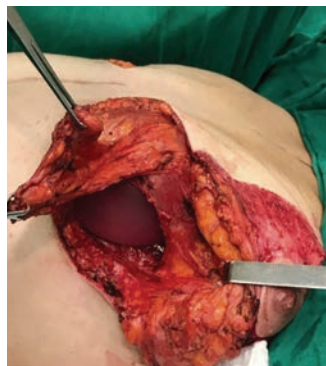


Figure 4A - Inferior flap is used to cover and protect the implant.

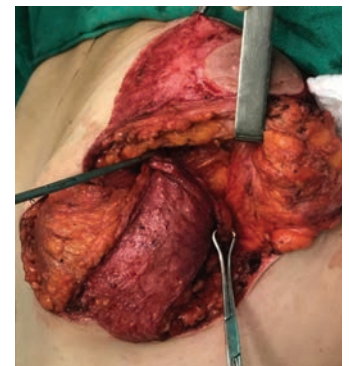

Figure 4B - Inferior flap is used to cover and protect the implant.

HOW I MARK: VERTICAL MASTOPEXY



BABIS RAMMOS, MD, FACS - UNITED STATES



BILL G. KORTESIS, MD, FACS - UNITED STATES



GAURAV BHARTI, MD, FACS - UNITED STATES

Markings

Preoperative markings are similar to those for a vertical reduction mammoplasty. The patient is marked in the upright standing position, and the following markings are made:

- Midline, from sternal notch to xiphoid
- Inframammary Fold
- Breast meridian (**Figure 1**).
- The new nipple location is marked by transposition of the inframammary fold to the front of the breast, at the level of the meridian. The top of the areolar opening is marked 1-2 cm above the new nipple position.
- With the use of a keyhole breast reduction marker (42 mm), the areola opening is marked (**Figure 2**).
- The breast is displaced, first laterally and then medially. Vertical lines are drawn from the lower portion of the new areola to a point 1 cm above the inframammary fold (**Figure 3**).
- Measurements are made bilaterally, from sternal notch to nipple, and from midline to ensure symmetry. Finalized markings are shown (**Figure 4**).

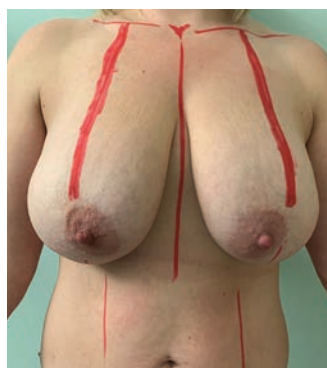

Figure 1 - The patient is marked in the upright standing position, and the following initial markings are made: Midline, from sternal notch to xiphoid; Inframammary Fold; Breast meridian.

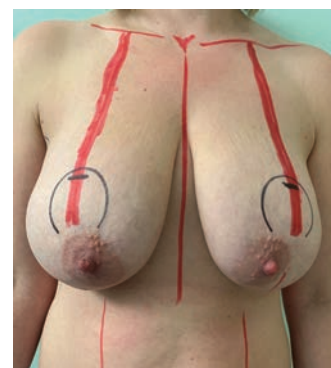


Figure 2 - The new areola opening is transferred on the superior breast parenchyma. The top of the areola is about 1-2 cm above the inframammary fold.

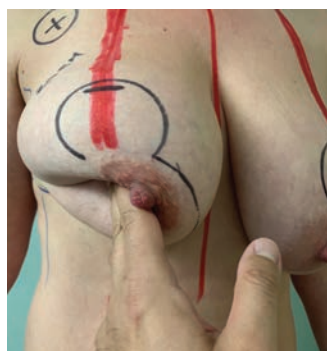

Figure 3 - The breast is displaced, first laterally and then medially. Vertical lines are drawn from the lower portion of the new areola to a point 1 cm above the inframammary fold.

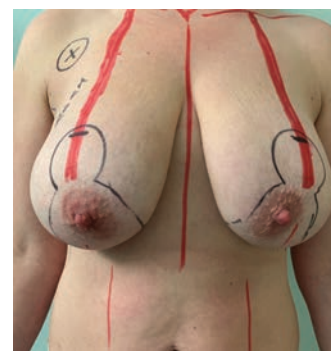


Figure 4 - Preoperative frontal view markings of a 38-year-old female with grade II ptosis.

- Intraoperative, the skin is tailor tacked, and the lower areola to inframammary fold distance is chosen on average at 7 cm. The patient is sat up to verify the mastopexy marks. The nipple areola complex is left in situ, and the intervening skin is deepithelialized. A superior pedicle is created, and appropriate vertical and horizontal amount of tissue is removed, and recorded. Vertical pillar sutures are placed, and the wounds are closed in layers. No drains are used, and the patient is discharged home the same day.

HISTORY SPOTLIGHT



RICCARDO F. MAZZOLA, MD - ITALY
Associate Editor, History of Medicine

JULIUS VON SZYMANOWSKI (1829-1868)

Julius von Szymanowski is certainly one of the most outstanding personalities of nineteenth century plastic surgery. Despite his early death, he contributed extensively to the progress of our specialty (Figure 1).



Figure 1 - Julius von Szymanowski (1829-1868)
(Courtesy of Klaas Marck, MD).

Life

Szymanowski was born in Riga, Latvia in 1829 to a Polish noble family. He studied at Tallin's Gymnasium in Estonia and entered Medical School at Dorpat University in present day Tartu, Estonia, graduating in 1856 with a thesis on leg amputation *Additamenta ad ossium resectionem* (Additions to Bone Resection). He trained in surgery with Georg von Adelman (1811-1888), Professor of Surgery, who replaced the Russian surgeon Nikolai Pirogov (1810-1881) at Dorpat University.

With his teacher, von Adelman, Szymanowski served with the Russian army in the Crimean War (1854-56). Having such great experience, he soon became a talented surgeon. Upon his return at Dorpat University, he prepared a habilitation thesis (1857), choosing a reconstructive topic: *Adnotationes ad Rhinoplasticen* (Notes on Rhinoplasty). The contents deal with a historical review of all the known cases of nasal reconstruction from the Italian Brancas (15th century), to the year 1856, when Szymanowski performed his first nasal repair. He listed and documented 225 cases from the literature. The following year he published a long article, *Zur Plastischen*

Chirurgie (On Plastic Surgery), mainly based on nasal reconstruction and lip repair, confirming his great interest in our specialty.

In 1858, he moved to the Imperial Alexander University in Helsinki where he was appointed Professor. During this period of time, he produced numerous papers and contributed to Pirogov's Atlas, *Surgical Anatomy of the Arteries and Fasciae*. While in Helsinki, in 1860, he married Adelaide, a Finnish lady.

In 1861, at the age of 32 years, he established himself in Kiev, Ukraine, where he was nominated Professor of Operative Surgery at St. Vladimir Imperial University Hospital. Despite his young age, he operated on numerous complicated cases and assembled all of them for his future textbook on plastic surgery, which was issued in 1865, in Russian: *Operatii na poverchnnosti Tchelovetcheskago Tela* (Operations on the surface of the human body) (1) (Figure 2). Soon after, he started its translation into German with the cooperation of his pupil Karl Wilhelm Ferdinand Uhde (1813-1883) from Braunschweig. The book was posthumously published in 1870 (Figure 3) (2).




Figure 2 - Title page of Szymanowski's textbook on Plastic Surgery published in Russian in 1865.

Continued on page 64

Regrettably, the following year he had been diagnosed a testicular carcinoma, which was excised by the famous surgeon, Nikolai Pirogov. The tumour eventually recurred and metastasized. Szymanowski died in 1868, aged 39.




Figure 3 - Title page of the German translation, posthumously issued in 1870.

Legacy

Szymanowski worked for more than ten years preparing his exhaustive textbook, *Operations on the surface of human body*, with 108 lithographic plates, containing more than 600 illustrations, drawn by the author himself, showing the numerous cases he treated during his short, but active career.

The book begins with a detailed description on the different flaps

available for reconstructive purposes and how to use them. It continues with the clinical application of the described basic techniques. More than 24 plates are devoted to explain skin flaps step-by-step, their rationale, how they should be outlined, transposed and sutured into position safely, to avoid formation of raw areas in the donor site. He introduced the concept of plastic surgical reconstruction unknown by his contemporaries, analyzing the tissue defects, trying to give them a geometrical form whenever possible and finally establishing an appropriate operative treatment plan. For this, he should be acknowledged as the real father of plastic and reconstructive surgery (4).

Closure of facial defects was one of the major concerns of Szymanowski's clinical work. This covers more than 75 plates in his book. If one carefully examines the different reconstructive surgical procedures proposed by Szymanowski, one notices that little has been added to the progress of plastic surgery since.

HE SHOULD BE ACKNOWLEDGED AS THE REAL FATHER OF PLASTIC AND RECONSTRUCTIVE SURGERY

From the numerous fascinating cases shown in his text, we shall take some examples into consideration. He described and illustrated an aesthetic operation for shortening a hanging nose, and modifying the naso-labial angle at the same time, by excising a bilateral triangular

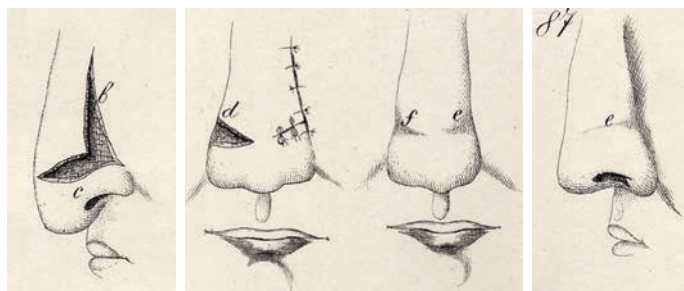


Figure 4 a, b, c - Correction of the hanging nose; a) before surgery; b) excision of a bilateral piece of skin; c) final result.

piece of skin and suturing the ensuing defect (Figure 4). A similar technique was first reported by the German surgeon J. F. Dieffenbach in 1845, without illustrations.

For closing a wide tissue loss of the oral commissure, he proposed the transposition of a submandibular skin flap. For microtia's correction, he advocated the use of different flaps outlined in the mastoid area. For the repair of the ala of the nose, he described the use of a naso-labial flap, whereas for closing a defect of the inner canthus he showed the transposition of the forehead flap. Use of a cross leg flap was also illustrated (Figure 5).

But his name is related to the correction of the ectropium. He described an operation, which eponimically bears his name, outlining a skin/tarsal strip, and fixing it in tension in an upward position with respect to the outer canthus (Figure 6). The procedure was further improved by the German ophthalmologist Herrman Kuhnt (1850-1925) and nowadays it is known as Kuhnt-Szymanowski operation.

In summary, it was a landmark of nineteenth century plastic surgery, which unfortunately was little known in the western world.

Conclusions

Julius von Szymanowski is scarcely quoted and very few biographies about him appeared in the literature. In the past, the only important publication was written by ISAPS Past President, Blair Rogers (3), who affirmed that: “Operations on the surface of human body contains more about plastic surgery than any other nineteenth century textbook.”

Recently, Klaas Marck, MD, a very enthusiastic Dutch plastic surgeon, wrote a complete, well documented book about Szymanowski, discovering numerous documents about this extraordinary surgeon in the libraries of the cities where he spent his life: Tartu, Helsinki, and Kiev and showing the environment where he lived. Those interested in obtaining more information about Szymanowski, are encouraged to refer to the book published by Klaas Marck*.



Figure 5 - Cross leg flap.

* The book can be purchased directly from the author at k.marck@chello.nl at a very reasonable price (20€, postal expense excluded.)

REFERENCES

1. Szymanowski J. Operatzij na Poverchnosti Tchelovetcheskago Tela (Operations on the Surface of Human Body). Kiev, Davidenko, 1865
2. Szymanowski J. Handbuch der operativen Chirurgie (Manual of Operative Surgery). Braunschweig; Vieweg, 1870
3. Rogers BO. Julius von Szymanowski. Plast Reconstr Surg 1979; 64: 465-78
4. Marck K. Another way of thinking. The life and works of Julius Szymanowski, the real father of plastic reconstructive surgery. Overveen; Ultgeverij Belvedere, 2019

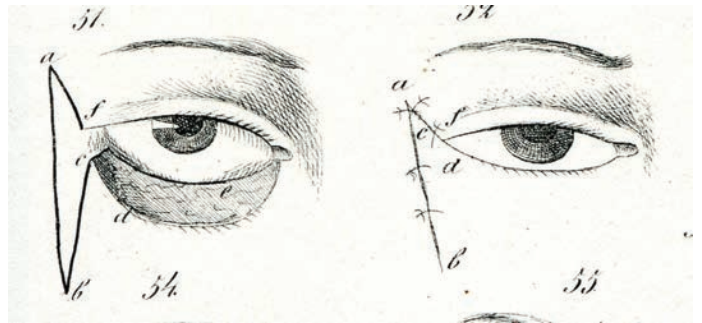


Figure 6 - The technique for ectropium correction; a) the skin/tarsal flap; b) the flap sutured into position.

IN MEMORIAM



FLAVIO SACCOMANNO

June 3, 1948 – March 30, 2019

Thank you for everything: your willingness, your enthusiasm, your rigor, your love for this profession, your time. - Pierfrancesco Cirillo - Vice President, AICPE

Long-time ISAPS member, Dr. Flavio Saccomanno, lost his life in the crash of his single-engine plane on March 30 in Castel Viscardo, near Orvieto, Italy.

His death left everyone shocked. He was an experienced pilot who was flying his acrobatic plane - as he had for 30 years. "It was his greatest passion after his family and his work," according to his friend and colleague, Pierfrancesco Cirillo. "He is no longer with us, Uncle Flavius, as many of us called him good-naturedly, because he never denied any help, advice, or some of his time to any of us. He is no longer with us, our friend - sincere, generous, polite, never intrusive but always present. The dinners we organized often were a moment of pleasure, of being together, of sharing an evening, chatting and laughing."

Born in Sao Paulo, Brazil, Dr. Saccomanno was a Roman by adoption. Co-founder and President of the *Italian Association of Aesthetic Plastic Surgery* (AICPE), he was a protagonist of Roman plastic surgery who trained dozens of colleagues. Above all, he was a beautiful person, educated, generous and never superior in spite of his exceptional talents - qualities recognized not only by colleagues, but also by the many patients who relied on him.

His loss will be felt by many who were full of affection in their words in the aftermath of the tragedy. According to his friend, Cirillo, "Flavio will miss us all, but of one thing I am sure: he died at a happy moment in his life and while he was doing something he loved."

Flavio Saccomanno leaves his wife and two daughters: one worked with him, the other lives in Brazil and had just given him a grandchild. "I am sure Flavio will always be present, like all the great Masters," Cirillo concludes, "because he left us a great inheritance."

His enthusiasm and intelligence will be greatly missed in the surgical community. ISAPS sends heartfelt condolences to the family.

Adapted from an article by Clarida Salvatori in Corriere Della Sera, March 31, 2019 and the notice of Dr. Saccomanno's passing by ISAPS member, Pierfrancesco Cirillo, on the AICPE website.

IN MEMORIAM

REMEMBERING A DEAR FRIEND - MAGNUM SHAHATEET, MD



MUTAZ Z. ALKARMI, MD, FRCS - JORDAN

It has always been difficult for me to go through the life of a friend in a few lines, but I'll try to convey to you an honest picture.



After graduation from medical school in Turkey, Magnum joined the Royal Medical Services in Jordan. When he finished his training in general surgery and passed his surgical fellowship in the UK, he joined "the elite group"

that is the plastic surgery department at King Hussain Medical Centre (KHMC). In 1981, I joined this elite group of late doctors: Shubailat, Ajluni, Shahateet, and Haddad, and doctor Basel Kirresh.

Magnum was very kind to me and as much as I was keen to learn, he was very helpful. He showed an early interest in hand and microvascular surgery. Soon he left for the United States to join the father of microsurgery, Dr. Harry Buncke in San Francisco, California. When he came back, it happened that we received a young German technician with complete amputation of his left hand at the wrist. After a long night, we successfully replanted his hand. This was the first case to be reported in Jordan and even in the area around us. Magnum, together with the

help of Dr. Shubailat, rapidly advanced the science and art of microsurgery. Multiple cases of amputated digits and limbs were successfully replanted. Free flaps soon became an easy reconstructive option.

Magnum's success was not only related to his skill in theatre, but also for his kindness and keen interest in helping others. When he left to work in the private sector, he carried with him not only his skills, but also the same attitude towards everyone around him. When I became head of the department, the number of qualified plastic surgeons had doubled with more fellows in training. He became Jordan's ISAPS National Secretary and was active in our local scientific activities. We kept a close relationship and when he decided to retire as National Secretary, he called me and showed his interest that I should replace him, which I consider as a kind gesture from him and with the help of good friends from our society, I was elected after him as ISAPS National Secretary.

Magnum managed to improve the art and science of plastic surgery, and in particular microsurgery, in Jordan tremendously. He will be always remembered as a kind, helpful gentleman. He is survived by his good wife, daughter, sons and grandsons.

ISAPS WELCOMES NEW MEMBERS

MARCH THROUGH MAY 2019

ARGENTINA

Paola CAJIDE, MD**
Fernando GLARIA, MD**
Rocio NACIR, MD**
Marlene PEREZ COLMAN, MD**
Francisco PEREZ RIVERA, MD
Valeria PITRA, MD**
Griselda POETA, MD**
Eliher VASQUEZ IGUARAN, MD**
Maria VIZCAY, MD**

AUSTRALIA

Fanny BALLIEUX, MD**
Sarah LONIE, MBBS (Hons), B Med Sci**

AUSTRIA

Rafic KUZBARI, MD
Paul LIEBMANN, MD**

BANGLADESH

Tanveer AHMED, FCPS, FACS
Kazi AHMED, FCPS, MRCS
Mohammad ALI, MS, FCPS
Mohammed AZAD, MS
Imran CHOWDHURY, FCPS
Shuva DEBNATH, MBBS, MS**
Masroor HASAN, FCPS, MS
Mohammad Ayub HOSSAIN, MS**
Zaman HUMAYRA, FCPS
Mirza ISLAM, FCPS
Mohammad KABIR, FCPS
Mohammad KAMAL, FCPS, MS
Mohammad KAMRUZZAMAN, FCPS, FRCS
Mostafa KHAN, MS*
Sayeqa KHONDKER, FCPS*
Kaushik MALLICK, MS
Mohammad MANNAN, FCPS
Munny MOMTAZ, FCPS, MS*
Afroza NAZNEEN, FCPS
Mohammad QUAMRUZZAMAN, FCPS, MS
Mohammad RAHMAN, DSS
Bidhan SARKAR, MS
Afrina SHARMIN, FCPS*
Syeda SHASHI, FCPS, MS
Sharmin SUMI, FCPS, MS*
Syed WAHEDUZZAMAN, FCPS, MS

BELARUS

Sergey MECHKOVSKI, MD
Diana PETROVA, MD, PhD

BELGIUM

Marwan ABBOUD, MD

BRAZIL

Bruno AKEL, MD**
Jorge LOPEZ MORAN, MD**

Rita NARIKAWA, MD*
Andres ORDENES, MD**
Francisco OYARCE, MD**
Andre VALIATI, MD*
Alexandre WADA, MD
Camila ZAKI, MD**
Eduardo ZANIN, MD**

BULGARIA

Boris TSVETKOV, MD**

COLOMBIA

Gustavo PERTUZ, MD

EGYPT

Wafaa ABDEL MOHSEN, MD**

GERMANY

Hans BUCHER, MD
Andrea CALETTI, MD**
Ron EPPSTEIN, MD
Michael HILLER, MD
Mario HOLDENRIED, MD
Steven MANN, MD**
Tobias METT, MD*
Achmed SCHEERSOI, MD

HUNGARY

Janos GYETVAN, MD

INDIA

Nupur AGGARWAL, MBBS, MS**
Chirag BHANSALI, MBBS
Jatin BHOJANI, MBBS, MS**
Ravindra Nath BHYRI, MS, MCh
Dharini DHARINI, MBBS, MS, MRCS(Eng)**
Baljinder GARG, MS, MCh
Joyce JESUDASS, MBBS, MS**
Vamseedharan MUTHUKUMAR, MBBS**
Santosh PANIGRAHY, MBBS, DNB*
Arjunan SARAVANAN, MBBS, MS, MCh*
Sneha SHARMA, MBBS, MS**
Srushti SHETH, MBBS, MS**
Sharma SHRIDATT, MBBS, MS**
Krishna SINGH, MBBS, MS**
Kanika SINGLA, MBBS, MS**
Archana SINHA, MBBS, MS**
Anoop SIVAKUMAR, MBBS, MS, MRCSEd**
Megha SODHI, MBBS, MS**
Prateek THAKUR, MBBS, MS**
Aniketh VENKATARAM, MBBS, MS, MCh*

IRAN

Razie JAFARI, MD**

IRAQ

Arwa ALMAJIDY, MD*
Bilal KAKA AMIN, MD

KENYA

Alex WAMALWA, MBChB**

LEBANON

Fadl CHAHINE, MD**

MEXICO

Emmanuel ARCEO MARTINEZ, MD**

Fernando Javier ARIAS ZATARAY, MD**

Luisa ARMAS GIRÓN, MD**

Andrea CARRILLO, MD**

Julio CASTILLO, MD**

Daniela Anahí CIAMBELLI ROMERO, MD**

Eduardo CORDERO ESTRADA, MD**

Partricio CORREA CÁMARA, MD**

John DAVIS AROSEMENA, MD**

Eduardo FLORES GONZÁLEZ, MD**

Carlos Francisco FORASTÉ ENRIQUEZ, MD**

José GALASO, MD**

Antonio GARCÍA RODRÍGUEZ, MD**

Marcos GONZÁLEZ LANDEROS, MD**

Veronica GUTIERREZ, MD

Elsa HARO ALVAREZ, MD**

Brandon HEFTYE SÁNCHEZ, MD**

Roberto HERÁNDEZ, MD**

Luis Miguel HERNANDEZ GARCIA, MD**

Amschell Robinsson IXCAMPARIC CHOLOTIO, MD**

William Erick LEÓN TORRES, MD**

Daniel LÓPEZ FABILA, MD**

Luis LÓPEZ-GARIBAY, MD**

Omar MALDONADO BADLLO, MD**

Carlos MCGREGOR GÓMEZ, MD**

Francisco Xavier MORALES MARIN, MD**

Mario MORÁN ROMERO, MD**

Luciano NAHAS COMBINA, MD**

David NAVARRO-BARQUIN, MD**

María Ferndanda NUÑEZ BURGOS, MD**

Alberto Gerardo O' FARRILL PACHECO, MD**

Diego Guibaldo OROZCO RODRÍGUEZ, MD**

Ivan ORTIZ MONASTERIO, MD**

Paul Manuel Ali OUDDANE ROBLES, MD**

Esteban PEREZ CEBREROS, MD

Génesis PINEDA ALDANA, MD**

Guillermo RAMOS GALLARDO, MD

Carlos Eduardo RODRÍGUEZ ANGUIANO, MD**

Loyda Alejandra RODRÍGUEZ LÓPEZ, MD**

Carlos RODRIGUEZ RODRIGUEZ, MD**

Claudia ROMERO RUIZ, MD**

Juan Jose RUIZ-TREVIÑO, MD

Josué Ernesto SAFADIT COMPRES, MD**

Jorge Alfonso SALINAS CRUZ, MD**

Argenis SÁNCHEZ PACHECO, MD**

Javier SÁNCHEZ PÉREZ, MD**

Ricardo Daniel SÁNCHEZ VÉLEZ, MD**

Jorge SERRANO, MD**

Javier SOLIS, MD

Cristian Danilo de Jesús TINEO SANTANA, MD**

Sergio VALLEJO-TORO, MD**

Edgar VARGAS FLORES, MD**

Rodrigo Alexander VELA INTRIAGO, MD**

Karol VERDEZOTO GAIBOR, MD**

Roy VILLAFRANCA ANDINO, MD**

Diana Florencia ZECEÑA URIBE, MD**

PERU

Karin MENDOZA, MD**

Maira MULDER, MD**

PHILIPPINES

Lourdes Josephine ANGLIONGTO-RAMOS, MD

POLAND

Szymon KOLACZ, MD, PhD

ROMANIA

Turan ABDULAZIS, MD

Ruxandra SINESCU, MD

RUSSIAN FEDERATION

Elena BYAKOV, MD

Andrew GURYANOV, MD, PhD

Robert GURYANOV, MD*

SPAIN

Juan Jose HARO, MD, PhD

TURKEY

Orhan BABUCCU, MD

Berfu BABUCCU, MD

Ozan BITIK, MD

Aysun BOLUKBASI MAMAK, MD

Mehmet GONULLU, MD

Zekeriya KUL, MD

Cem PAYASLI, MD

UNITED KINGDOM

Fateh AHMAD, BSc(Hons), MBBS(Hons), MD, FRCS(Plast)

Ioannis ALEXANDRIDIS, MD

Jamil HAYEK, MD*

Amir NAKHDJEVANI, MBBS, MRCS, FRCS

UNITED STATES

Libby COPELAND-HALPERIN, MD**

Lisa GFRERER, MD, PhD**

Jennifer HEIN, MD

Neal MOORES, MD**

Sheila NAZARIAN MOBIN, MD, MMM

Joseph RUCKER, MD, FACS

Rhett WILLIS, MD**

VENEZUELA

Gabriel GIMENEZ MORENO, MD

VIETNAM

Van Phung NGUYEN, MD

* indicates Associate Member

** indicates Associate Resident/Fellow Member

MEETINGS CALENDAR

ISAPS COURSE – TURKEY

DATES: 20 June – 23 June 2019
LOCATION: Istanbul, TURKEY
VENUE: Hilton Convention Center
EMAIL: yagiz@seveneventcompany.com
WEBSITE: <http://www.eurasian2019.org/>



MIPSS 2019

DATES: 20 June – 22 June 2019
LOCATION: Marbella, SPAIN
VENUE: H10 Andalucía Plaza Hotel
CONTACT: Vanessa Garcia
TEL: 34-951-775518
EMAIL: info@mipss.eu
WEBSITE: <https://www.mipss.eu/>



LIVESTREAM WEBINAR – GLUTEAL AUGMENTATION

DATES: 21 JUNE 2019
ORIGINATING FROM: ISTANBUL, TURKEY
FACULTY: DR. RAUL GONZALEZ
DEADLINE TO REGISTER – 10:00 AM NEW YORK TIME – JUNE 18



THE AESTHETIC CRUISE 2019

DATES: 23 June – 04 July 2019
LOCATIONS: Italy, Malta, Greece, Montenegro, Croatia, Slovenia
CHAIR: Dr. Melinda Haws
CO-CHAIR: Dr. Joseph Hunstad
ASAPS CONTACT: Debi Toombs
TEL: 1-562-799-2356
EMAIL: debi@surgery.org
CRUISE CONTACT: Bob Newman
EMAIL: bnewman.mail@cruisebrothers.com
WEBSITE: www.surgery.org/cruise2019



7TH LIVE SURGERY COURSE MARBELLA

DATES: 27 June – 28 June 2019
LOCATION: Marbella, SPAIN
VENUE: Hotel Barcelo Marbella
CONTACT: Carolina Lerussi
TEL: 34-952-775346
EMAIL: carolina@cirumed.es
WEBSITE: <https://livesurgery.cirumed.es/index.html>



13TH BODY LIFT COURSE

DATES: 04 July – 06 July 2019
LOCATION: Geneva, SWITZERLAND
VENUE: Hotel President Wilson
CONTACT: International Plastic Surgery Advanced Course (IPSAC)
TEL: 33-04-72837769
EMAIL: charles@ipsac.eu
WEBSITE: <http://www.ipsac.eu/>



HIGH DEFINITION LIPOSCULPTING USING THE PAL MICROAIRE SYSTEM MASTER'S COURSE

DATES: 11 July – 12 July 2019
LOCATION: Barcelona, SPAIN
VENUE: Instituto De Benito
CONTACT: Dr. Ahmad Saad
TEL: 34-932-530282
EMAIL: drsaad@institutodebenito.com
WEBSITE: <https://www.institutodebenito.com/pal-high-definition-masters-course/>



VI SÃO PAULO BREAST SYMPOSIUM 2019

DATES: 06 September – 07 September 2019
LOCATION: São Paulo, BRAZIL
VENUE: WTC (World Trade Center)
CONTACT: Dr. Joao Carlos Sampaio Goes
TEL: 55-11-3167-2200
EMAIL: clinica@sampaio Goes.com
WEBSITE: <http://saopaulobreastsymposium.com.br/>



ISAPS SYMPOSIUM – COLOMBIA

DATE: 18 September 2019
LOCATION: Santa Marta, COLOMBIA
VENUE: Estelar Santamar Hotel & Convention Center
CONTACTS: Damaris Romero – President of Congress
Maria Isabel Cadena – National Secretary ISAPS for Colombia
TEL: +57 314 213 3377
EMAIL: xxxviicongresonacionalsccp2019@gmail.com
WEBSITE: <http://www.xxxviicongresosccp.com/>



5TH WORLD CONGRESS OF PLASTIC SURGEONS OF LEBANESE DESCENT

DATES: 19 September – 21 September 2019
LOCATION: Beirut, LEBANON
VENUE: Hilton Beirut Habtoor Grand Hotel
CONTACT: Dr. Bishara Atiyeh
TEL: 961-3-340032
EMAIL: batiyeh@terra.net.lb
WEBSITE: <http://www.lspras.com/>



ADVANCED TECHNIQUES IN FACIAL REJUVENATION: MASTERY OF THE SUB SMAS AND DEEP NECK LIFT

DATES: 28 September – 29 September 2019
LOCATION: St. Louis, MO, UNITED STATES
CONTACT: Tabitha Crawford
VENUE: Practical Anatomy and Surgical Education Bioskills Facility
TEL: 1-314-977-7334
EMAIL: tabitha.crawfordobialo@health.slu.edu
WEBSITE: <https://cvent.me/ZRz1m>



ISAPS SYMPOSIUM – AUSTRALIA

Immediately preceding the annual ASAPS meeting
DATE: 03 October 2019
LOCATION: Brisbane, Queensland
VENUE: Sofitel
CONTACT: Anna Cornwell
EMAIL: acornwell@theproductionhouseevents.com.au
WEBSITE: <https://aestheticplasticsurgeons.org.au/event/2019-isaps-conference>



CSAPS/ISAPS SYMPOSIUM – CANADA

DATE: 03 October 2019
LOCATION: Vancouver, BC, Canada
FOCUS: Body and Breast – Redefined
VENUE: Fairmont Hotel Vancouver
CONTACT: Tara Hewitt
TEL: (905) 655-9889
FAX: (905) 655-7319
EMAIL: csapsoffice@gmail.com
WEBSITE: www.csaps.ca



ISAPS SYMPOSIUM – POLAND

Immediately following the XVII Congress of Polish Society of Plastic, Reconstructive and Aesthetic Surgery, October 10-11
DATE: 12 October 2019
LOCATION: Poznan, POLAND
CONTACT: Dr. Maciej Kuczynski
EMAIL: kuczynski@ptchprie.pl
WEBSITE: <https://www.isaps.org/event/isaps-symposium-poland/>
REGISTRATION: <https://www.17zjazd.ptchprie.pl/lang-en/>



ISAPS SYMPOSIUM – UK – RHINOPLASTY

DATE: 12 October 2019
LOCATION: London, UK
VENUE: Wellcome Collection
CONTACT: Aleiya Lonsdale
TELEPHONE: +44 (0) 20 3196 4375
EMAIL: Aleiya.lonsdale@easyfairs.com/isaps-symposiumuk@easyfairs.com
WEBSITE: www.isaps-symposium.co.uk



EASAPS BIENNIAL MEETING ON FACIAL REJUVENATION

DATE: 17 October – 19 October 2019
LOCATION: Bruges – BELGIUM
VENUE: Congress Centre Oud Sint-Jan
CONTACT: MZ Congressi srl
TEL: +39 02 66802323
FAX: +39 02 6686699
EMAIL: congress@easaps.org
WEBSITE: http://www.easaps.org/?page_id=2238



ISAPS SYMPOSIUM FOR RESIDENTS AND FELLOWS

Immediately preceding the EASAPS Biennial Meeting on Facial Rejuvenation
DATE: 17 October 2019
LOCATION: Bruges, BELGIUM
VENUE: Oud St Jan Convention Center
EMAIL: easaps@mzcongressi.com
WEBSITE: <http://www.easaps.org>



3RD NORWEGIAN-AMERICAN AESTHETIC SURGERY MEETING (NAAM3)

DATES: 25 October – 26 October 2019
LOCATION: Oslo, NORWAY
VENUE: Oslo Military Society
CONTACT: Kaisa Filtvedt
EMAIL: oslomeeting@naam.no
WEBSITE: <https://www.naam.no>



ISAPS SYMPOSIUM – SPAIN

DATES: 06 November 2019
LOCATION: Madrid, SPAIN
TOPIC: Patient Safety and Prevention of Complications Immediately preceding AECEP Annual Meeting
TEL.: +34 91 571 93 90
EMAIL: info@bnyco.com



ISAPS COURSE – MONACO – LIVE PLASTIC SURGERY (FOCUS: FACE)

DATES: 07 November – 09 November 2019
LOCATION: MONACO
VENUE: Grimaldi Forum
CONTACT: Dr. Henry Delmar & Catherine Decuyper
EMAILS: henry@henry-delmar.com & catherine@euromedicom.com
WEBSITE: <https://www.euromedicom.com/lps/en/participants/about-isaps-course-monaco.html>



ISAPS F.A.S.T. PROGRAM – MOSCOW

DATES: 15 November – 16 November 2019
LOCATION: Moscow, RUSSIAN FEDERATION
VENUE: Manturova Institute
TOPIC: Aesthetic Body Surgery – Part 3 of 3
CONTACT: Anna Pimenova
EMAIL: orgcom@isapsfast.ru
WEBSITE: www.isapsfast.ru



ISAPS COURSE – SAUDI ARABIA

Immediately following the Saudi Plastic Surgery Care Society (SPSCS) Meeting
DATES: 05 December – 07 December 2019
LOCATION: Riyadh, SAUDI ARABIA
VENUE: Crown Plaza Riyadh RDC Hotel & Convention Center
CONTACT: Anna Theresa P. Baltao, RM, BCHS
EMAIL: info@saudiplasticsurgery.org
WEBSITE: <http://www.saudiplasticsurgery.org/>



FULL CIRCLE RHINOPLASTY LIVE SURGERY MEETING

DATES: 13 December - 15 December 2019
LOCATION: Istanbul, TURKEY
VENUE: Florence Nightingale Hospital
CONTACT: Yagiz Tutuncuoglu
TEL: 90-533-7471423
EMAIL: yagiz@seveneventcompany.com
WEBSITE: <http://www.rhinoplastyistanbul.org/>



ISAPS COURSE – BELGIUM CADAVER DISSECTION COURSE

DATES: 16 January - 18 January 2020
LOCATION: Liege, BELGIUM
NOTE: Limited to 32 participants
CONTACT: Mrs. Anne-Marie Gillain
TEL: 32 (0)4 242-5261
FAX: 32 (0)4 366-7061
EMAIL: amgillain@chu.ulg.ac.be
WEBSITE: www.isapscourse.be



MEETINGS CALENDAR CONTINUED

ISAPS COURSE – GREECE

DATES: 09 April – 11 April 2020

VENUE: War Museum www.warmuseum.gr

LOCATION: Athens, GREECE

CONTACT PERSON: Vicky Delidimitriou, vdelidimitriou@noufio.gr

TEL: +30 210-2775219

FAX: +30 210-2714437

WEBSITE: www.isapscourseathens2019.gr

ORGANIZING SECRETARIAT: NOUFIO www.noufio.gr



SECONDARY OPTIMIZING AESTHETIC SURGERY SYMPOSIUM (SOS) 2020

DATES: 31 August – 01 September 2020

LOCATION: Vienna, AUSTRIA

VENUE: Andaz Belvedere Vienna Hotel

CONTACT: Barbara Boeld

TEL: +49-89-18-90460

EMAIL: congress@bb-mc.com

WEBSITE: <http://www.sos2020.eu>



ISAPS COURSE – SOUTH AFRICA

DATES: 20 March – 22 March 2020

LOCATION: Cape Town, SOUTH AFRICA

VENUE: Lord Charles Hotel, Somerset West

CONTACT: Hendrika van der Merwe

TEL: +27-21-981-3081

EMAIL: congress.isaps@eliteconfer.co.za

WEBSITE: <http://www.isapscourse.co.za>

NOTE: Optional post-course safari to Thornybush Game Lodge, March 23-25.

See website for additional information and cost.



GUESS WHO ANSWER



Gustavo Jimenez Muñoz Ledo, MD - Mexico

Assistant National Secretary for Mexico & Member, ISAPS Education Council

Our Assistant National Secretary participating in charrería, a traditional equestrian practice in Mexican livestock herding communities, which is the national sport recognized by UNESCO. In its origins, it facilitated the coexistence among farmers from different states of the country. The techniques of this practice were transmitted to the younger generations within the families. Nowadays, associations and schools specially dedicated to charrería train members to participate in national and international competitions. The outfits, as well as equipment required, such as clothing, saddles, bridles and spurs, are designed and produced by local artisans, forming additional components of the traditional practice.

ISAPS EXECUTIVE OFFICE STAFF

45 Lyme Road, Suite 304
Hanover, NH, USA 03755
Phone: 1-603-643-2325
Fax: 1-603-643-1444
Email: ISAPS@isaps.org
Website: www.isaps.org

EXECUTIVE DIRECTOR

Catherine Foss
ISAPS@isaps.org

GRAPHIC DESIGNER

Jodie LeBrun
Abstracts@isaps.org

MEMBERSHIP SERVICES MANAGER

(Ms) Jordan Carney
Membership@isaps.org

EDUCATION EVENTS MANAGER

Michele Nilsson, CMP
Registrar@isaps.org

ISAPS NEWS MANAGEMENT

EDITOR-IN-CHIEF

Nina Naidu, MD (United States)

ASSOCIATE EDITOR, HISTORY OF MEDICINE

Riccardo Mazzola, MD (Italy)

MANAGING EDITOR

Catherine B. Foss (United States)

CHAIR, COMMUNICATIONS COMMITTEE

Tim Papadopoulos, MD (Australia)

EMERITUS EDITOR

J. Peter Rubin, MD, FACS (United States)

ISAPS BOARD OF DIRECTORS, COMMITTEE CHAIRS & APPOINTMENTS 2018 - 2020

Board of Directors

President
President-Elect
1st Vice President
2nd Vice President
3rd Vice President
Secretary
Treasurer
Historian
Parliamentarian
National Secretaries Chair
Education Council (EC) Chair
EC Vice-Chair
Past President
Trustee
Trustee
Executive Director

Dirk Richter, Germany
Nazim Cerkes, Turkey
Lina Triana, Colombia
Gianluca Campiglio, Italy
Arturo Ramirez-Montana, Mexico
Ivar van Heijningen, Belgium
Kai Schlaudraff, Switzerland
Peter Scott, South Africa
Tim Papadopoulos, Australia
Michel Rouif, France
Vakis Kontoes, Greece
Ozan Sozer, USA
Renato Saltz, USA
Nina Naidu, USA
Fabian Cortinas, Argentina
Catherine Foss, USA

Standing Committee Chairs

Executive
Nominating
Membership
By-Laws
Communications/Branding/Marketing
Patient Safety
Journal Operations
Finance & Investment
Newsletter
Residents & Fellows
Women Plastic Surgeons

Dirk Richter, Germany
Renato Saltz, USA
Fabian Cortinas, Argentina
Tom Davis, USA
Tim Papadopoulos, Australia
Foad Nahai, USA
Nazim Cerkes, Turkey
Kai Schlaudraff, Switzerland
Nina Naidu, USA
Maria Wiedner, Germany
Teresa de la Cerda, Chile

Education Council

Vakis Kontoes, Greece - Chair
Ozan Sozer, USA - Vice Chair

Ad Hoc Committee Chairs

Humanitarian
Industry Relations
Insurance
Global Survey
Global Accreditation
Visiting Professor
Global Alliance
Continental Communication
New Talents
50th Anniversary
Patient Education
Social Media
Webinar
E-Learning Development
International Board Examination

Tunc Tiryaki, Turkey & Nina Naidu, USA
Kai Schlaudraff, Switzerland
Nigel Mercer, United Kingdom
Dennis von Heimburg, Germany
Ozan Sozer, USA & Ivar van Heijningen, Belgium
Renato Saltz, USA
Mark Jewell, USA
Andre Cervantes, Brazil
Al Aly, UAE
Joe Hunstad, USA
Stefano Danilla, Chile
Simone Hellmann, Germany
Nazim Cerkes, Turkey
Gianluca Campiglio, Italy
Daniel Kalbermatten, Switzerland

DISCLAIMER:

ISAPS News is not responsible for facts as presented by the authors or advertisers. This newsletter presents current scientific information and opinions pertinent to medical professionals. It does not provide advice concerning specific diagnosis and treatment of individual cases and is not intended for use by the layperson. Readers are strongly advised to confirm that the information complies with the latest legislation and standards of practice. ISAPS, the editors, the authors, and the publisher will not be responsible for any errors or liable for actions taken as a result of information or opinions expressed in this newsletter. Copyright © 2019 by the International Society of Aesthetic Plastic Surgery, Inc. All rights reserved. Contents may not be reproduced in whole or in part without written permission of ISAPS.

The background of the advertisement is a vibrant, multi-colored nebula or dust cloud. It features a mix of bright blue, yellow, orange, and pinkish-purple hues, all set against a dark, almost black background. The colors are soft and ethereal, with a grainy texture that suggests fine particles or light scattering. In the top right corner, there is a dark grey rectangular box containing the text 'MERZ AESTHETICS®'.

MERZ AESTHETICS®

Inspired by you

Your Practice.
Your Patients.
Our Priority.

You're listening to patients. We're listening to you.

Now we're introducing an expanded suite of products, procedures and support to help you address a full range of patient and practice needs for the face, neck, décolletage, hands and more.

Learn more at merz.com

Quality you can feel



POLYTECH



SAVE THE DATE

INTERNATIONAL SOCIETY OF AESTHETIC PLASTIC SURGERY

SEPTEMBER 2 - 5, 2020
VIENNA, AUSTRIA

WELCOME TO VIENNA, THE MOST LIVEABLE CITY IN THE WORLD

A young and vibrant city - full of historical buildings, culture and hip restaurants! The ideal place to learn from the Best in the World of aesthetics, to reconnect with your international friends, or simply to enjoy Austrian hospitality. There is no better place to celebrate our 50th anniversary.

Vienna calling!

HOT TOPICS

- Live Surgery on Complication Cases (SOS)
- Cadaver courses
- Marking courses
- Best & worst case session
- Problems and solutions panels
- Migraine surgery labs
- Best of the World competition
- Reboot your practice
- Innovations in industry
- Social media training

www.isapsvienna2020.com